

guna
medical device

GUNA COLLAGEN MEDICAL DEVICES

REPLACE

REINFORCE

REPAIR

ABSTRACT BOOK

PLAY SURE
doping free

collagenmd.guna.com

INDEX

9 **FOREWORD**

11 **LITERATURE REVIEW ON COLLAGEN:**
Giarda F., Gervasoni F., Parente A., Robecchi Majnardi A.
Collagen for injectable use in the treatment of musculoskeletal disorders: a literature overview.

ANATOMICAL REGIONS



12 **NECK**

SIMFER 2024

13 *Brambilla R., Fontana R., Rivolta V., Laiosca L., Ausenda C.D., Perucca L.*
Ultrasound-guided periarticular injectable therapy with collagen in cervical pain due to involvement of the zygapophyseal facet joints.

I.S.MU.L.T. 2024

14 *Brambilla R., Rivolta V., Treppiccione O., Laiosca L., Ausenda C.D., Perucca L.*
Collagen for the treatment of cervical pain syndrome related to zygapophyseal joint involvement.

15 *Yen T., Cimino P., Padul J., Rocca G., Giranio G., Emedoli D., Iannacone S., Brugliera L.*
Ozone Therapy in combination with focal collagen-based injections on a patient with severe Cervicalgia.

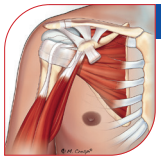

16 **SHOULDER**

SIAGASCOT 2025

17 *Del Chiaro A., Khayyat A., Stella S.M.*
Ultrasound-guided infiltration treatment for post-operative shoulder adhesion.

SIMFER 2025

18 *Lorusso R., Balsamo F., Ciaramella I., Perrero L., Invernizzi M.*
Shoulder tendinopathy in paraplegic patients: safety and efficacy of an injection treatment based on collagen.

19 *Ristori R., Cecchetto L.*
Combined treatment with collagen and PRP for osteoarticular and tendon disorders: a case series on shoulder osteoarthritis and achilles tendinopathy.

SIMFER, SIOT 2024

20 *Rocco A., Cardarola A.*
Therapeutic outcome in patients with rotator cuff injury: injectable treatment with collagen.

SIOT 2024

21 *Zagarella A., Deromedis B., Frezza V., Garuti F., Emili I., Randelli P.S.*
Ultrasound-guided collagen injectable therapy in partial rotator cuff tears (RC).

I.S.MU.L.T. 2024

22 *Rocco A., Cardarola A.*
Therapeutic outcome in patients with rotator cuff injury: injection treatment with collagen.

23 *Yen T., Cimino P., Padul J., Rocca G., Giranio G., Emedoli D., Iannacone S., Brugliera L.*
Treatment of shoulder instability in a young female with Ehlers-Danlos Syndrome.

SIMFER 2023

24 *Mutti M.*
Calciphic Tendinosis: A novel injectable collagen-based therapeutic solution.



25 SPINE – LUMBAR SPINE

SIMFER 2023

26 *Sgarbi L., De Pascalis M., Mulas S.*
Comparison of the combined intramuscular injection treatment of Ozone/collagen therapy and the intramuscular injection treatment of Ozone therapy for chronic low back pain due to discopathy.

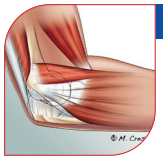

27 ELBOW

SICM 2025

28 *Acquati Lozej J.G.P., Comitani S.*
Ulnar nerve syndrome at the elbow in a violinist resistant to conventional therapies.

SIMFER 2025

29 *Fusi C., Lopresti E.*
Treatment of medial epicondylitis with collagen injections: a case series.

SICM 2024

30 *Bonucci P.L., Gerace E.*
Col 1 ultrasound-guided injections in tendinopathy LE: case series.

ISOKINETIC 2024

31 *Bonucci P.L.*
Ultrasound-guided injections of collagen in tendinopathy: a case series.



32 HAND - FINGER

ISOKINETIC 2026

33 *De Vitis R., Guzzini M., Rocchi L., Passiatore M., Lombardi L.*
Collagen injections for hand and wrist tendon and ligament injuries in elite athletes.

34 *Tognon S., Fantoni I., Inglese A., Turchetta S., Necchi M.*
Biotherapies in extensor carpi ulnaris tendonitis: case series in rugby players.

SICM 2025

35 *Del Giudice M., Di Cesare A.*
Collagen injection therapy of stenosing tenosynovitis of the flexor tendons of the fingers ("trigger finger"): a case series.

SIMFER 2025

36 *Cavallo E., Falli A., Scavia A., Barberis M.F., Niola M.L., Invernizzi M.*
Treatment of post-surgery hand adhesion syndrome with collagen: two case reports.

37 *Del Giudice M., Di Cesare A.*
Infiltrative therapy for stenosing tenosynovitis of the flexor tendons of the fingers ("trigger finger"): treatment of 22 cases with MD TISSUE Collagen Medical Device.

SIAGASCOT 2024

38 *Formis A.*
Recurrence of de Quervain in a musician: combined focused shock wave treatment and injectable therapy using collagen.

SICM 2023

39 *Mirisola G., Mangone G., Scarselli M.*
Case series: injectable treatment with collagen in patients with rhizoarthrosis.

SIMFER 2023

40 *Giarda F., Parente A., Cattaneo F., Gervasoni F., Robecchi A., Caronni A.*
Use of collagen in the treatment of symptomatic rhizoarthrosis: preliminary results.

41 *Valgimigli F.*
Collagen-based injectable therapy in the rehabilitation pathway of bilateral rhizoarthrosis.

SIMFER 2023 - SICM 2023

42 *Pesaresi A., Ricci V., Gervasoni F., Giarda F., Robecchi Majnardi A., Andreoli A.*
Trigger finger ultrasound-guided injectable treatment with collagen. Initial clinical evidence.

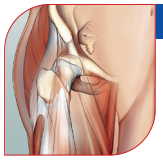

43 HIP

ISIAT 2025

44 *Rando G., Ferraris L., Foti C.*
Inguinal Disruption (ID) in an elite-level athlete: non-surgical management with collagen injections (MD-Tissue/MD-Muscle), ESWT, and targeted rehabilitation.

SIOT 2024

45 *Fioruzzi A., Mazzoleni M., Verga L., Rahali L., Radaelli A., Randelli F.*
Evaluation of the effectiveness of a collagen-based medical device in the injectable treatment of greater trochanteric pain syndrome.

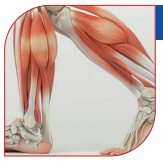

46 LEG - CALF

ISOKINETIC 2026

47 *Baldassarri M., RIcciardello R., Ghinelli D., Perazzo L., Buda R.*
Biology first, load later: injectable collagen priming in insertional tendinopaty.

SIMFER 2024

48 *Malfitano C., Dallavalle J., Casto E., Agnello R.*
Effectiveness of injectable collagen in pain from amputation neuroma: a case study.

ISOKINETIC 2024

49 *Cera A., Bonsanto F.*
Ideal path of functional recovery for return to play associated with collagen MD-Tissue in padel player affected by quadriceps tendinopathy.

ISOKINETIC 2023 - I.S.MU.L.T. 2023

50 *Fusi C., Mutti M.*
Collagen injection treatment in medial gastrocnemius muscle injury.



51 KNEE

SIOT 2025

52 *Ruosi L.. Bruno A.A.M., Arnaldi E., De Donato M., Basso M.*
Meniscus transplant with allograft and augmentation with collagen scaffold: a case report.

SIOT 2024

53 *Borelli P.*
Injectable treatment with collagen for patellar tendinopathy. A case report.

SIAGASCOT 2024

54 *Placella G.*
Painful knee prosthesis: Can injectable collagen help us? Case report.

SIMFER 2023

55 *Laiosca L., Brambilla R., Rivolta V., Ausenda C.D., Perucca L.*
Tendonitis of the biceps femoris muscle treated with collagen-based mesotherapy.

ISPRM 2022

56 *Markovic B.*
Effects of combined application of PRP and Guna MD-KNEE Collagen in the treatment of moderate osteoarthritis of the knee. Pilot Study.



57 ANKLE

SIAGASCOT 2026

58 *Formis A., Zanini A., Bettinsoli P.F.*
High-grade tear in achilles tendinosis: infiltration treatment with MD TISSUE combined with needling.

SIAGASCOT 2025

59 *Fusi C., Lopresti E.*
Injection treatment with type I collagen for anterior talofibular ligament injuries in athletes: a case series.

ISOKINETIC 2025

60 *Lopresti E., Fusi C.*
Injectable COL1 on ATFL injuries: an observational case-control study.

SIOT 2025

61 *Boselli P.M., Cocuzza M.*
Percutaneous tenorrhaphy of the Achilles tendon associated with intratendinous collagen infiltration: clinical evaluation.

SIOT 2024

62 *Boselli P.M., Cocuzza M.*
Minimally invasive Achilles tendon suture: combined with intraoperative injectable collagen treatment.

63 *Placella G., Biavardi N.*
Treatment of achilles tendinopathy with injectable collagen in diabetic patients: case series.

SIMFER 2024

64 *Fusi C., Lopresti E.*
Collagen injectable treatment for anterior talofibular injuries in athletes: a case series.

SIMFER 2023

65 *Mirisola G., Mangone G., Scarselli M., Cecchi F.*
Case series on injectable treatment with collagen in patients with post-traumatic ankle arthrosis.



66 FOOT

SIAGASCOT 2025

67 *Boselli P.M., Cocuzza M.*
Intratendinous collagen injection combined with surgical treatment of acute Achilles tendon injuries.

SIAGASCOT 2024

68 *Placella G.*
The treatment of Achilles tendinopathy using injectable collagen in patients with diabetes: case series.

I.S.Mu.L.T. 2024

69 *Fusi C., Lopresti E.*
Injectable treatment with collagen on anterior fibular talar ligament injuries in sports patients: a case series.

SIMFER 2022

70 *Giarda F., Agostini A., Colonna S., Dalla Costa D., Rogliani R., Sciumè L., Ciriolo S., Beretta G.*
The use of collagen-based medical devices in the treatment of Morton's Neuroma: a case series.



71 MUSCLES

ISOKINETIC 2024 / I.S.Mu.L.T. 2024

72 *Ricciardello S., Baldassarri M., Ghinelli D., Perazzo L., Buda R.*
Efficiency and safety of collagen injections for treatment of hamstring tendinopathy.

FOREWORD

This Abstract Book is a collection of clinical cases treated with Guna's collagen for injection, presented during national and international Medical Congresses.

They constitute real-world evidence on the use of Guna Collagen Medical Devices for the injection treatment of various musculoskeletal pathologies.

The contents of this Abstract Books are organized by anatomical region for easy consultation.

Guna Collagen Medical Devices are **CE-marked class III Medical Devices** containing **collagen**. They can be administered intra-articularly, or extra-articularly with intramuscular, intratendinous, subcutaneous, intradermal injections, or mesotherapy.



Each 2 ml vial of a Guna Collagen Medical Device contains collagen of swine or equine origin and additional ingredients of mineral or plant origin, or vitamins, specific for each item of the range.

They are available in packs of 5 or 10 sterile vials.

LITERATURE REVIEW ON COLLAGEN

Collagen for injectable use in the treatment of musculoskeletal disorders: a literature overview.

Federico Giarda[1], Fabrizio Gervasoni[2], Andrea Parente[3], Antonio Robecchi Majnardi[4]

1.Unit of Rehabilitation Medicine and Neurorehabilitation, Department of Neuroscience, ASST Niguarda Hospital, Milan, Italy
2. Unit of Physical and Rehabilitation Medicine, "Luigi Sacco" University Hospital, ASST Fatebenefratelli-Sacco, Milan, Italy
3. Department of Biomedical Sciences for Health, Università degli Studi di Milano, Milan, Italy) 4. Department of Neurorehabilitation Sciences, Istituto Auxologico Italiano, IRCCS, Milan, Italy

Introduction

Musculoskeletal disorders (MSDs) affect 15-20% of the population, and in the 70% of cases they cause chronic pain. The incidence and the prevalence of MSDs are increasing worldwide following the global aging of population, thus determining growing suffering and costs. Musculoskeletal conditions are also the highest contributor to the global need for rehabilitation. [Cieza A., et al. The Lancet, 2021].

Many MSDs are characterized by a quantitative and/or qualitative alteration of collagen. The imbalance between degradation and synthesis processes of collagen, influenced by proinflammatory cytokines and reactive oxygen species (ROS), is responsible for the progressive histological and functional weakening of musculoskeletal system structures, such as tendons. As a matter of fact, tendons' mechanical properties are strongly influenced by the composition of the extracellular matrix (ECM), mainly made up of collagen [Bosman FT, et al. J Pathol. 2003; Kannus P,. Scand J. Med. Sci Sports 2000]. Tissue-engineering strategies involve the use of scaffolds, cells and/or bioactive factors to promote tendon regeneration through a natural process (in case of damaged or lost tissue) [Randelli F, et al. Cells 2020].

During the onset of Osteoarthritis (OA), an acute inflammatory process is established, and pro inflammatory factors cause the degradation of ECM, including collagen. [Hunter DJ, et al. Lancet 2019]. For this reason, intra-articular collagen injections have been investigated as a possible symptomatic adjuvant or stand-alone treatment for OA and as a cost-effective solution compared with HA. [Martin Martin LS, et al. BMC Musculoskelet Disord. 2016].

The interactions between muscle cells and ECM play a key role in the reparative processes of muscle tissue, especially when it's subjected to mechanical stress. Quantitative or qualitative alterations of collagen at the ECM level can become the cause of inappropriate muscle regeneration, favoring, or supporting pathological processes [Thorsteinsdóttir S, et al. Dev Biol. 2011].

Considering the increase of clinical evidences and studies on regenerative collagen [Giarda F, et al. MR Volume 39 – N.1 – Marzo 2023], our aim is to provide an updated overview of the literature on the use of collagen-based medical devices (CMD) in the musculoskeletal field.

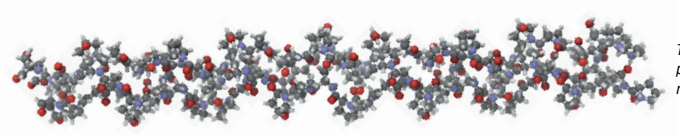

The structural unit of collagen is characterized by the presence of three polypeptide chains with a left-handed orientation, coiled to form a right-handed triple helix.

Materials and Methods

Using PubMed, Web of Science and EMBASE, we identified relevant papers published up to April 2023 concerning the use of CMD in the treatment of musculoskeletal disorders.

Results

In vitro exposure: The results of the in vitro studies by Randelli F. et al. on the use of collagen preparations, in the form of injectable CMD on human tenocytes obtained from healthy fragments of the gluteus minimus tendon, show that the tenocytes cultured on MD-Tissue, compared to controls, have a higher proliferation rate and higher migration potential. [Randelli F, et al. Cells. 2018] This therapeutic approach also influences the collagen turnover pathways and represents an input involving mechanotransduction phenomena, proposing itself as a bio-scaffold with a reparative and regenerative action. [Randelli F, et al. Cells. 2020].

Clinical evidence: The results of the seven studies which evaluated the effects of intra-articular collagen injections for knee OA showed that the intra-articular administration of collagen may stimulate chondrocytes to produce hyaline cartilage and hinder the normal inflammatory response leading to fibrous tissue formation, reducing symptoms and improving functionality. The use of collagen as an intra-articular treatment for knee OA was found not only to be effective, but also safe with negligible side effects. [Tarantino D, et al. IJERPH 2023].

Intra and peri-articular collagen injection was also found to be effective in patients with coxarthrosis (Kellgren-Lawrence I and II). Some clinical trials had in fact demonstrated statistically significant results in reducing pain and improving function, with lasting effects up to 3 months [Tivchev P. Bulgarian Journal of Orthopedics and Trauma 2012; Giovannangeli F. PRM 2017; Milano E. PRM 2018].

In a pilot study, injectable collagen was shown to be effective in reducing pain and improving function in subjects affected by lateral epicondylitis, one and three months after treatment. The 50 enrolled patients were treated with a series of five injections at weekly intervals. (Corrado B, et al. Muscle Ligaments and Tendons Journal 2019).

In a randomized, controlled, single-blind study of 43 patients, the use of injectable collagen in the treatment of myofascial pain within masseter muscles was compared with the intramuscular injection of lidocaine and saline. The results showed a significant reduction of pain intensity in muscle activity, quantified by surface electromyography, in all groups for both variables analyzed. However, the most consistent improvements were observed in the subgroup treated with collagen. [Nitecka-Buchta A, et al. Pain Res Manag 2018].

Discussion and Conclusion

Analyzing the literature available to date, collagen is proposed as a promising approach in the treatment of pain and functional recovery related to musculoskeletal pathologies. No significant side effects have ever been reported in previous studies. However, the actual literature shows a span of studies that vary in methodology, samples analyzed, pathologies treated, and outcomes evaluated. Discrepancies between studies still do not allow to draw conclusive considerations, however CMD could represent a novel safe and cost-effective approach to musculoskeletal disorders. Further studies are needed to more precisely define the indications and limitations of the method.

NECK



ULTRASOUND-GUIDED PERIARTICULAR INJECTABLE THERAPY WITH COLLAGEN IN CERVICAL PAIN DUE TO INVOLVEMENT OF THE ZYGAPOPHYSEAL FACET JOINTS

Brambilla Rossana1, Roberta Fontana2, Valeria Rivolta1, Laiosca Laura1, Carlo Domenico Ausenda1, Laura Perucca3

1, U.O.C. Riabilitazione Specialistica, Ospedale San Carlo Borromeo - ASST Santi Paolo Carlo, Milano, Italia

2, Scuola di Specializzazione in Medicina Fisica e Riabilitazione, Università degli studi di Milano, Milano, Italia

3, IRCCS Istituto Auxologico italiano, Dipartimento di Scienza Biomediche per la Salute-Università degli Studi di Milano, Milano, Italia

INTRODUCTION: Chronic cervicalgia associated with degenerative disorders of the cervical spine is a common and challenging condition to treat. Involvement of the interapophyseal facet joints is considered the primary source of cervical pain in up to 70% of cases. The most widely used interventional techniques are invasive (1): anesthetic blockade of the medial branch of the cervical nerve, radiofrequency ablation of the medial branch of the cervical nerve and intra-articular interfacet injection. In our study, we performed a non-invasive, ultrasound-guided periarticular injectable treatment at the level of the cervical facet joints using collagen.

In preclinical studies, collagen has been shown to act as a bioscaffold for colonization by cells that produce signals promoting tissue healing (monocytes, platelets, macrophages, fibroblasts). Exogenous collagen stimulates the synthesis, maturation and secretion of collagen fibers by fibroblasts and contributes to capsular and ligamentous stabilization as well as to the reorganization of the muscular fascia (2).

MATERIALS AND METHODS: We recruited 10 outpatients with a diagnosis of cervicalgia primarily related to interapophyseal facet joint involvement, present for more than 6 weeks, resistant to analgesic and conventional anti-inflammatory therapy. Patients who had undergone physical or interventional therapies in the previous 6 weeks or who had ongoing neoplastic or infectious diseases were excluded. The joint pathology was confirmed with at least one instrumental examination (radiological in 5 patients, MRI in 4 patients, CT scan in 1 patient). Clinically, the facet joint press-palpation test and the cervical extension-rotation test were positive. The patients, 3 males and 7 females, were aged between 38 and 86 years, with an average age of 71.9 years. Patients were evaluated at baseline (T0) and at the end of treatment (T1). The following were used: Numeric Rating Scale (NRS) for pain, on a 10-point scale, and the Neck Disability Index Questionnaire (NDIQ) for disability related to neck pain. The GUNA MEDICAL DEVICE NECK MD-NECK, a class III medical device collagen-based, was used. Five treatment sessions were performed at biweekly intervals.

In each session, the patients were treated with MD-NECK collagen, 2 vials (total 4 ml), administered periarticularly under ultrasound guidance. The collagen was divided into four 0.5 ml injections on each side. A 28 G, 13 mm needle was used. The facet joints at the levels of C3-C4, C4-C5, C5-C6, and C6-C7 were identified ultrasonographically with a 12 Hz linear probe. The injection was performed using an out-of-plane technique, keeping the ultrasound probe positioned longitudinally on the articular profile (3).

RESULTS: All patients reported a progressive clinical improvement with a reduction in pain and disability related to neck pain. Pain on the NRS scale decreased in all patients by a delta of 3 to 6 points. The minimal clinically important difference of 3 points on the NRS scale was observed in 100% of the patients.

Disability improved in all patients: a minimal clinically important difference of at least one level on the NDIQ scale was observed in 90% of them.

- 3 patients: severe disability to minimal
- 4 patients: moderate disability to minimal
- 1 patient: severe disability to moderate
- 1 patient: invalidity to moderate disability
- 1 patient: Disability score improved but remained in the minimum level

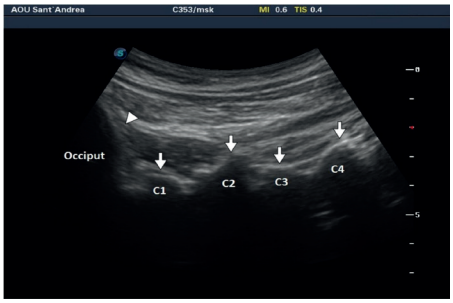

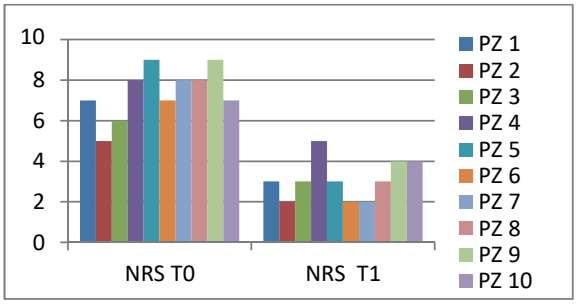

CONCLUSIONS: Collagen can reduce joint pain and inflammation and promote bioregenerative processes. MD-NECK collagen is a useful, safe, easy-to-use reparative and regenerative solution. In our case series, no side effects related to collagen or the injection technique were observed. In our patients, periarticular injectable treatment with MD-NECK, a class III medical device collagen-based, administered periarticularly in the cervical interapophyseal area under ultrasound guidance, has been shown to reduce pain and improve function in a challenging and highly prevalent chronic condition for which few effective conservative treatments are available.

BIBLIOGRAPHY:

1. Consensus practice guidelines on intervention for cervical spine (facet) joint pain from a multispecialty international working group. Reg Anesth Pain Med 2022 Jan;47(1):3-59.
2. Effect of a collagen-based compound on morpho-functional properties of cultured Human tenocytes (Randelli F. at all. Cells 2018)
3. Ultrasound guided intervention of cervical spine and nerves (Ke Vin Chang et al, Phis Med Rheabil Clin 2018)

12° I.S.Mu.L.T. Congress
12-13 Aprile 2024 - Roma

Sistema Socio Sanitario
Regione Lombardia
ASST Santi Paolo e Carlo

COLLAGEN FOR THE TREATMENT OF CERVICAL PAIN SYNDROME RELATED TO ZYGAPOPHYSEAL JOINT INVOLVEMENT.

Brambilla Rossana, Rivolta Valeria*, Treppiccione Orazio**, Laiosca Laura*, Ausenda Carlo Domenico* , Perucca Laura ****

(*) Rehabilitation Hospital Unit, ASST Santi Paolo e Carlo,San Carlo Borromeo Hospital. Milan
(**) Physical Medicine and Rehabilitation Specialisation school University ofMilan,
(***) IRCCS Auxological Institute, Department of Biomedical Sciences for Health, University of Milan, Italy.

INTRODUCTION:

Chronic cervicalgia associated with degenerative problems of the cervical spine is a frequent and difficult-to-treat condition.
Involvement of the posterior zygapophyseal facet joints is considered the main source of pain in up to 70 % of cases.
The most common interventional techniques available are invasive:

- Anaesthetic blocking of the medial branch of the cervical nerve
- Radiofrequency ablation of the medial branch of the cervical nerve
- Intra-articular zygapophyseal injection

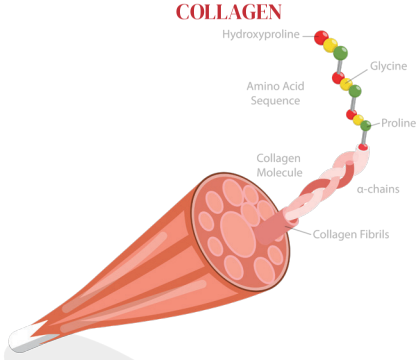

METHODS:

The study involved 3 patients referred to the physiatric outpatient clinic for persistent cervicalgia for more than 6 weeks, associated with muscle stiffness and joint limitation, resistant to analgesic and systemic anti-inflammatory therapy.
Gender: 1 M, 2 F
Age, 86 yrs, 47 yrs, 38 yrs.
All patients underwent an imaging examination with MRI without contrast of the cervical spine for diagnosis and exclusion of neoplastic pathology.

The Segmental Objective Examination showed:

- Limitation of the cervical P-ROM to medium levels in two cases, to initial levels in one case
- Presence of muscle contracture and trigger points at the level of the middle trapezius muscle
- Positive Extension-Rotation test for accentuation of pain related to the posterior interapophyseal facet joints

The patients were assessed at time zero, at the start of treatment, and at time 1, one week after the end of treatment.
The Visual Analogic Scale (VAS) for pain and the Neck Disability Index Questionnaire (NDIQ) for cervicalgia-related disability were administered.
The site of the zygapophyseal facet joints at levels C3-C4, C4-C5, C5-C6, C6-C7, was revealed using ultrasound with a 12 Hz linear probe, and marked.
Total injection sessions 5. In each weekly session the patients were treated with MD-NECK collagen administered by periarticular mesotherapy. 13 mm 28G needle, 4 points on each side of the neck injected freehand to a depth of 13 mm at the level of the bilaterally identified zygapophyseal joints (total 4 ml).
At the level of the most painful trigger points of the middle trapezius muscle, 3 + 3 injections per side were performed in the first 3 sessions, subcutaneous mesotherapy with a 13 mm 28G needle with Tr14 in vials (total 4 ml).

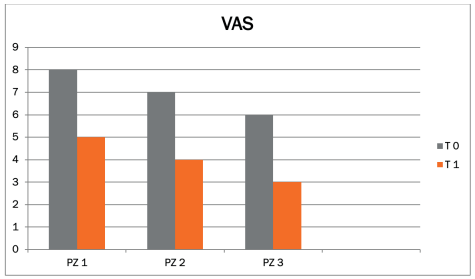

VAS	T 0	T1
PZ 1	8	5
PZ 2	7	4
PZ 3	6	3

RESULTS:

All patients reported progressive clinical improvement.
The VAS was reduced in all patients:
VAS 8 -> 5
VAS 7 -> 4
VAS 6 -> 3
The NDI improved in all patients:
21 (42%) severe disability -> 14 (28%) moderate disability
12 (27%) moderate disability -> 9 (20%) minimal disability
11 (22%) moderate disability -> 8 (16%) minimal disability
Periarticular injection treatment with MD-NECK, a class III medical device made from collagen, is a useful, safe and easy-to-use restorative and regenerative solution.
Collagen can reduce joint pain and inflammation and promote bioregeneration processes.
In this study, joint treatment with collagen was combined with treatment of the cervicoscapular myofascial inflammatory component with the Tr14 complex to accelerate the patients' functional recovery.

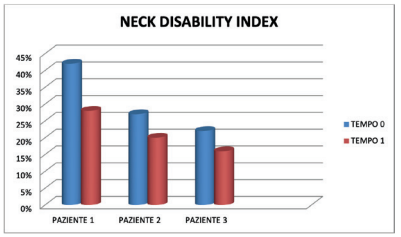

NECK DISABILITY INDEX	T0	T1
PZ 1	21 (42%) severe disability	14 (28%) moderate disability
PZ 2	12 (27%) moderate disability	9 (20%) minimal disability
PZ 3	11 (22%) moderate disability	8 (16%) minimal disability

CONCLUSIONS:

Injection treatment with MD-NECK collagen using an ultrasound-assisted periarticular mesotherapy technique is a safe and effective practice that can be used as a valuable tool for the treatment of a difficult, high-prevalence, chronic disease with few conservative solutions available.

REFERENCES:

1. Consensus practice guidelines on intervention for cervical spine (facet) joint pain from a multispecialty international working group. Reg Anesth Pain Med 2022 Jan;47(1):3-59.
2. Randelli F et al. The Collagen-Based Medical Device MD-Tissue Acts as a Mechanical Scaffold Influencing Morpho-Functional Properties of Cultured Human Tenocytes. Cells. 2020 Dec 8;9(12):264
3. Godek P. Collagen Therapy in Lumbar Spondylosis - a Pilot Study. Does the Route of Administration Matter? Ortop Traumatol Rehabil. 2019 Dec 31;21(6):427-436.

12° I.S.Mu.L.T. Congress
12-13 Aprile 2024 - Roma

I.R.C.C.S. Ospedale San Raffaele
Gruppo San Donato

OZONE THERAPY WITH COLLAGEN-BASED FOCAL INJECTIONS ON A PATIENT WITH SEVERE CERVICALGIA

Yen Tao-Yu MS[1], Cimino Paolo MD[1], Padul Jeffrey David MD[1], Rocca Gregorio MD[1] Giranio Giorgia MD[1], Emedoli Daniele PT[1], Iannacone Sandro MD[1], Brugliera Luigia MD PhD[1]
Affiliations: [1]Department of Rehabilitation and Functional Recovery, IRCCS San Raffaele Scientific Institute, Milan, Italy

INTRODUCTION:

Effectiveness of the therapeutic combination of Ozone Therapy and Collagen-Based Focal injection on patients with severe neck pain
Neck pain (Cervicalgia) is one of the most common disorders worldwide, with around 75% of the population having once throughout their lifetime.
The incidence rate varies by gender. It happens more frequently in females, especially those between 40 and 60.
Following lower back pain and depression, neck pain is now the third main health issue leading to absenteeism.

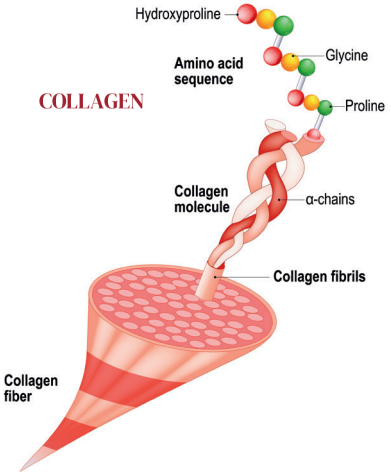

CLINICAL CASE:

A 51-year-old female, a bank clerk, came to our outpatient clinic of San Raffaele Hospital (Milan, Italy) in October 2023, complaining about severe neck pain, causing her an unacceptable change in her quality of life in the past few months.
She underwent a right mastectomy due to breast cancer (2015) and cycles of post-interventional chemotherapy with radiotherapy.
On 23rd July 2023, she went to the Accident and Emergency of Fidenza Hospital (Parma, Italy) for severe cervical pain, bilateral ear pain, subjective dizziness and tremours on the upper limbs.She had a cervical X-ray showing no vertebral fracture but spondyloarthritis with moderate physiological curve reduction. The brain CT is normal. A&E discharged her with the prescription of NSAIDs and muscle relaxant (Dicloreum+Thiocolchicoside) for one week; however, without benefit.

For the persistence of unstopping pain, the patient had a cervical MRI without contrast showing:

- On the C5-C6 level, the disc protrusion causes the anterior epidural closure and mild reduction in the width of the conjugation foramina (more on the right to the left).
- On the C6-C7 level, the disc protrusion presents medio-posteriorly and slightly compressing the dural sac (Thecal sac).

During the Neurosurgical visit, she underwent a peridural injection without benefit. Therefore, she was prescribed Gabapentin, Tizanidin, Dexamethasone, Tramadol, and Oxycodone by oral administration; still, the pain was not totally under control.
During medical examination, visit, she had an intense muscle contraction on the trapezoid and both the superficial and deep cervical paravertebral muscles. Combining Ozone Therapy and Collagen-Based Focal injection may meet the therapeutic requirement.
The programme for this patient consists of the following on the trapezoid and cervical paravertebral muscles:

- Ten times Ozone Therapy:
  - O2 / O3 concentration: 5 - 8 µg in the syringe of 50 mL and the needle of 27 Gauge
- Ten times Collange-Based Focal injection:
  - 1 vial of Guna MD-Muscle of 2mL in the syringe of 5 mL and the needle of 27 Gauge

NB: Current therapy:

- 1 packet of Magnesium Pidolate per day for a month
- 4 drops of Clonazepam before sleep

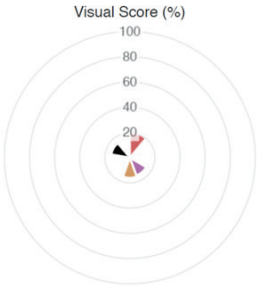

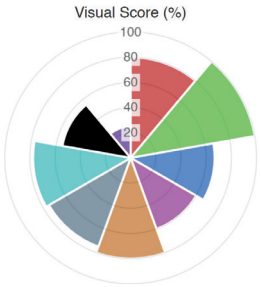

Physical functioning: 20 %
Role limitations due to physical health: 0 %
Role limitations due to emotional problems: 0 %
Energy/fatigue: 15 %
Emotional well-being: 16 %
Social functioning: 0 %
Pain: 0 %
General health: 15 %
Health change: 0 %

SF-36 Pre-Treatment

Physical functioning: 80 %
Role limitations due to physical health: 100 %
Role limitations due to emotional problems: 66.7 %
Energy/fatigue: 60 %
Emotional well-being: 80 %
Social functioning: 75 %
Pain: 77.5 %
General health: 55 %
Health change: 25 %

SF-36 Post-Treatment

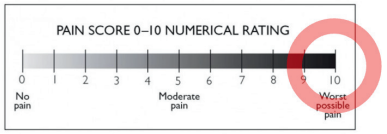

NRS – Pre Treatment

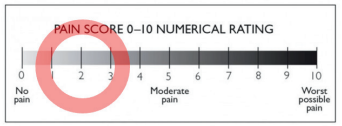

NRS – Post Treatment

CONCLUSIONS:

This clinical case demonstrates the effectiveness of combining ozone therapy and collagen-based focal injection treatment with Guna MD-Muscle in a patient with severe neck pain and functional limitation due to intense muscle contraction.

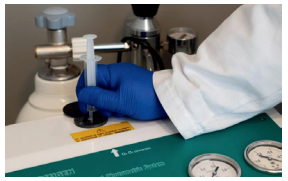

REFERENCES:

1. Retrospective observational study of intramuscular oxygen-ozone therapy for the treatment of neck pain: cervical paravertebral injection. Ucar D, Uçar S, Özcan Ç, Polat Ö, Çaçan MA, Uçar BY.Med Gas Res. 2020 Oct-Dec;10(4):170-173. Doi: 10.4103/2045-9912.286980.
2. Comparison between Collagen and Lidocaine Intramuscular Injections in Terms of Their Efficiency in Decreasing Myofascial Pain within Masseter Muscles: A Randomized, Single-Blind Controlled Trial. Nitecka-Buchta A, Walczynska-Dragon K, Batko-Kapustecka J, Wieckiewicz M.Pain Res Manag. 2018 Jun 3;2018:8261090. doi: 10.1155/2018/8261090. eCollection 2018

SHOULDER

4th ANNUAL MEETING

ULTRASOUND-GUIDED INFILTRATION TREATMENT FOR POST-OPERATIVE SHOULDER ADHESION



Andrea Del Chiaro, Director of Orthopedics and Traumatology UOC, Lucca Hospital
S. Al Khayyat, Rheumatology, University of Siena
S. M. Stella, University of Pisa

INTRODUCTION:

Post-operative adhesion syndrome (AS) is the most common cause of persistent pain and limited range of motion in patients undergoing rotator cuff (RC) reconstruction and subacromiodeltoid (SAD) bursectomy. Management of AS can be conservative (physical/manual therapy, cortisone/collagen injections) or surgical. Treatment is essential for the transition from the first (passive mobilization) to the second (active mobilization) phase of post-operative rehabilitation. Collagen creates a protective barrier on the tissues, preventing the onset of future adhesions.

MATERIALS AND METHODS:

We recruited 30 patients who had undergone arthroscopic rotator cuff reconstruction (supraspinatus tendon reinsertion), SAD bursectomy, and had developed adhesion syndrome. Patients were evaluated clinically and ecographically for signs suggesting adhesion fibrosis. Two ultrasound-guided injections of anesthetic and 2 ml of the collagen medical device MD-Tissue (Guna S.p.A., Italy) were performed 4 and 6 weeks after surgery with the aim of detaching existing adhesions and preventing their reformation. The effectiveness of the procedure was assessed based on improved functional scores and the formation of a hypo-anechoic interface between the supraspinatus and deltoid.

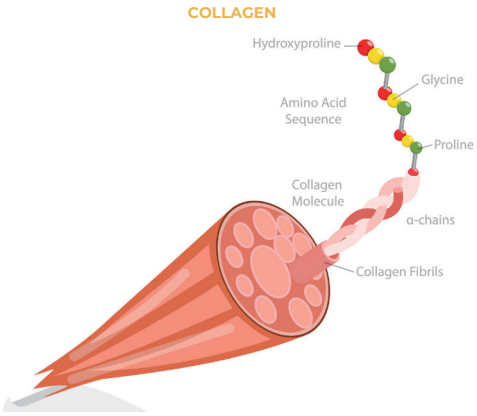

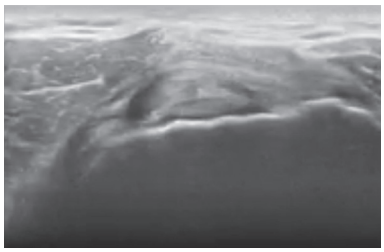

Reconstructed supraspinatus tendon; the subacromial space appears hyperechoic, consistent with postoperative scar tissue formation.

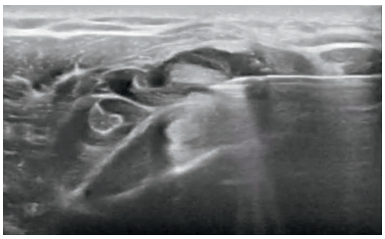

Insertion of the needle into the subacromial space and injection of local anesthetic.
Initial distension of the subacromial space is visible.

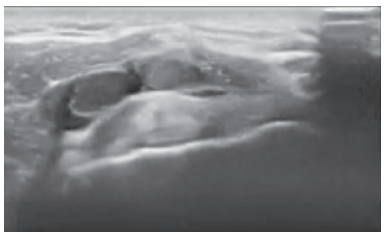

Final result following MD-TISSUE collagen infiltration.
A marked expansion of the subacromial space and expansion of the scar tissue are observed.

RESULTS:

The quick-DASH score at 4 weeks was 48.6 ± 9.3. Ultrasound evaluation demonstrated the formation of hyperechoic nodules suggestive of adhesion fibrosis. Four weeks after surgery, the first infiltration with MD-TISSUE was performed in all cases. Clinical evaluation six weeks after infiltration showed a quick DASH score of 27.2+7.6, and ultrasound evaluation showed the formation of a hypo-anechoic interface in 23 of 30 cases (77%). A second infiltration of the same type was performed six weeks later. The DASH score at eight weeks was 15.8+8.2, and the interface formed in 28 cases (93%).

CONCLUSION:

Ultrasound-guided infiltration into the subacromial space with the collagen medical device MD-TISSUE represents a valid therapeutic choice in the treatment of postoperative adhesion syndrome following RC reconstruction thanks to its scaffold and mechanical barrier function. Collagen acts as an anti-adhesion agent, limiting the formation of scar tissue by affecting the remodeling phase, allowing tissue healing and improving function. It may be a valuable, cost-effective, and safe biomaterial for use in the treatment of patients in whom corticosteroid injections are best avoided due to the risk of damaging the recently repaired tendon.

BIBLIOGRAPHY:

1. Randelli F, Sartori P, Carlomagno C, Bedoni M, Menon A, Vezzoli E, Sommariva M, Gagliano N. The Collagen-Based Medical Device MD-Tissue Acts as a Mechanical Scaffold Influencing MorphoFunctional Properties of Cultured Human Tenocytes. Cells. 2020 Dec 8;9(12):2641.
2. Godek P, Szczepanowska-Wolowiec B, Golicki D. Collagen and platelet-rich plasma in partial-thickness rotator cuff injuries. Friends or only indifferent neighbours? Randomised controlled trial. BMC Musculoskelet Disord. 2022 Dec 20;23(1):1109.
3. Corrado B, Bonini I, Chirico VA, Filippini E, Liguori L, Magliulo G, Mazzuoccolo G, Rosano N, Gisonni P. Ultrasound-guided collagen injections in the treatment of supraspinatus tendinopathy: a case series pilot study. J Biol Regul Homeost Agents. 2020 May-Jun;34(3 Suppl. 2):33-39. ADVANCES IN MUSCULOSKELETAL DISEASES AND INFECTIONS - SOTIMI 2019.

SIMFER
SOCIETÀ ITALIANA DI MEDICINA FISICA E RIABILITATIVA
The Italian Society of Physical and Rehabilitation Medicine

UPO UNIVERSITÀ DEL PIEMONTE ORIENTALE

POSTER N. 17

53° CONGRESSO NAZIONALE SIMFER
RICERCA E INNOVAZIONE IN MEDICINA FISICA E RIABILITATIVA
NAPOLI
23 | 26 NOVEMBRE 2025



SHOULDER TENDINOPATHY IN PARAPLEGIC PATIENTS: SAFETY AND EFFICACY OF AN INJECTION TREATMENT BASED ON COLLAGEN

Rita Lorusso[1], **Francesca Balsamo**[1], **Igino Ciaramella**[2], **Luca Perrero**[1], **Marco Invernizzi**[2]

[1] University Hospital SS. Antonio e Biagio e Cesare Arrigo, Alessandria
[2] UNIUPO University of West Piedmont

AOU AL Azienda Ospedaliero Universitaria di ALESSANDRIA Santi Antonio e Biagio e Cesare Arrigo

INTRODUCTION

Shoulder tendinopathy is one of the most common shoulder disorders, particularly in paraplegic patients with spinal cord injury who use a wheelchair daily. Functional overload of the shoulder girdle due to propulsion and transfer activities causes a high incidence of rotator cuff disorders (RCT), often associated with subacromial bursitis and tendinopathy. The most common therapies are pharmacological (NSAIDs/paracetamol), physical/instrumental (physiotherapy, Pilates, ultrasound, shock waves, functional electrical stimulation), cortisone injections (very limited use), PRP, collagen, and surgery only in selected cases. Collagen is a regenerative treatment for tendons, promoting tissue remodeling and restoring function with a high safety profile in paraplegic patients with comorbidities. The aim of this study is to evaluate the effectiveness of mesotherapy injections with a class III collagen-based device for injection, MD-SHOULDER (Guna S.p.A., Milan, Italy), in paraplegic patients with shoulder tendinopathy after a physical assessment and administration of the WUSPI (Wheelchair User's Shoulder Pain Index) scale, as well as ultrasound imaging.

MATERIALS AND METHODS

Five paraplegic patients (1F, 4M, ages 50 to 63) were selected. They were admitted to the Neurorehabilitation Unit of the "T. Borsalino" AOU-AL Rehabilitation Center between May and June 2025. They were regular wheelchair users and had shoulder pain attributable to rotator cuff tendinopathy (RCT), confirmed by physical assessment and ultrasound. A cycle of five mesotherapy injections was performed over four weeks (30G 13mm needle), according to the following protocol:

- Week 1: Two administrations (three days apart) of MD-SHOULDER collagen medical device (2 ml) (Guna S.p.A., Milan, Italy) + Arnica Heel Complex (2.2 ml) (Heel Gmbh, Baden- Baden, Germany)+ Lidocaine 1 ml;
- Weeks 2, 3, and 4: One weekly administration of MD-SHOULDER (2 ml) + Lidocaine 1 ml.

The injections were performed: at the ultrasound-detected sites corresponding to bursitis, tenosynovitis of the long head of the biceps, and supraspinatus and subscapularis tendon injuries; at the sites of maximum pain reported by the patient, corresponding to clinical trigger points.
The following were performed:

- Clinical-functional assessment with specific tests for the RCT

Musculotendinous ultrasound examination (long head of the biceps brachii, supraspinatus and subscapularis tendons, and subacromiodeltoid bursa)

- Administration of the WUSPI scale for the subjective assessment of pain related to daily activities

At T0 pre-treatment
At T1 post-treatment (1 week after the last administration)

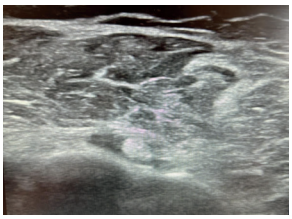

Patient 1
Long head of the biceps brachii with tenosynovitis (effusion)
PRE-TREATMENT

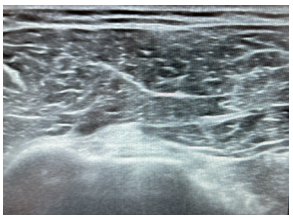

Patient 1
Long head of the biceps brachii
POST TREATMENT

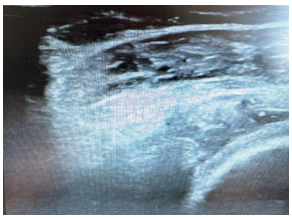

Patient 2
Supraspinatus tendinosis
PRE-TREATMENT

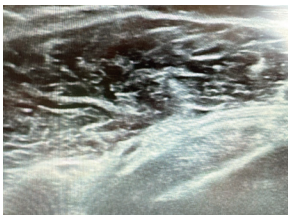

Patient 2
Supraspinatus
POST TREATMENT

RESULTS

All patients at T0 had positive results on specific tests (Jobe test - supraspinatus test), including two who also tested positive on the Lift Off test (for the subscapularis).
At T1, both tests were negative in all patients.
The mean WUSPI score showed a reduction of 52.2% (range: 40% - 73.1%). The values at T0 ranged between 67 and 110, while those at T1 ranged between 18 and 63.
The improvement in joint range of motion (ROM) refers to:

- Active abduction: mean increase of 32°, from 88° ± 4° at T0 to 120° ± 26° at T1
- Passive abduction: mean increase of 32°, from 106° ± 5° at T0 to 138° ± 21° at T1
- Active flexion: mean increase of 32°, from 100° ± 18° at T0 to 132° ± 20° at T1
- Passive flexion: mean increase of 61°, from 113° ± 8° at T0 to 174° ± 5° at T1

Clinically, a reduction in patient-reported trigger point tenderness was observed, as well as a subjective improvement in mobility in all treated patients. No local or systemic pre- and/or post-procedural adverse effects were observed in all treated patients and at any week of treatment.

CONCLUSIONS

The mesotherapy injection protocol with MD-SHOULDER (Guna S.p.A., Milan, Italy) has proven effective in the treatment of shoulder tendinopathy in paraplegic patients who use a wheelchair for their main activities of daily living. The results show a reduction in pain symptoms measured by the WUSPI scale, an increase in ROM and negative results on specific tests (Jobe and Lift Off), a reduction in peritendinous effusion, and an ultrasound-based improvement in tendon fiber quality due to the reparative and regenerative action of collagen. The targeted ultrasound-guided approach and the specific treatment of trigger points is safe, well-tolerated, and free of adverse effects, even in paraplegic patients. Further studies with a larger sample size will serve to confirm the efficacy and long-term reproducibility of the results observed so far.

BIBLIOGRAPHY:

1. Randelli F. et al Effect of a Collagen-Based Compound on Morpho-Functional Properties of Cultured Human Tenocytes. Cells. 2018 Dec 6;7(12):246.
2. Mason B. et al Managing shoulder pain in manual wheelchair users: a scoping review of conservative treatment interventions. Clin Rehabil. 2020 Jun;34(6):741-753.
3. Corrado B. et al Ultrasound-guided collagen injections in the treatment of supraspinatus tendinopathy: a case series pilot study. J Biol Regul Homeost Agents. 2020 May-Jun;34(3 Suppl. 2):33-39.

SIMFER
SOCIETÀ ITALIANA DI MEDICINA FISICA E RIABILITATIVA
The Italian Society of Physical and Rehabilitation Medicine

POSTER N. 63

53° CONGRESSO NAZIONALE SIMFER
RICERCA E INNOVAZIONE IN MEDICINA FISICA E RIABILITATIVA
NAPOLI
23 | 26 NOVEMBRE 2025



COMBINED TREATMENT WITH COLLAGEN AND PRP FOR OSTEOARTICULAR AND TENDON DISORDERS: A CASE SERIES ON SHOULDER OSTEOARTHRITIS AND ACHILLES TENDINOPATHY

Riccardo Ristori Emergency Medicine, Cecina
Luca Cecchetto DNP, CEO and Founder of Centro Medico Salus Itinere, Livorno

INTRODUCTION

Shoulder osteoarthritis (OA) and Achilles tendinopathy are highly prevalent degenerative conditions both in the general population and among athletes. Shoulder OA causes chronic pain, stiffness, and functional limitation, significantly impacting athletic performance and daily activities. Achilles tendinopathy, particularly common among runners and marathon runners, is associated with persistent pain and the risk of chronicity.
Conventional therapies—physiotherapy, anti-inflammatory drugs, hyaluronic acid injections—often offer limited or temporary benefits. Regenerative treatments consisting on a combination of a medical device based on collagen for injection and PRP (Platelet-Rich Plasma), have recently shown increasing potential. Collagen acts as a structural bioscaffold, with a repairing and regenerative effect, stimulating the synthesis of new collagen, while PRP, rich in growth factors, stimulates tissue regeneration. Combining them in a single injection, as in this case series, could optimize clinical outcomes, reduce recovery times, and improve therapeutic adherence in both conditions.

MATERIALS AND METHODS

Three athletes with chronic symptoms were treated: a 40-year-old woman, a competitive volleyball athlete, with grade 2 (Kellgren–Lawrence) shoulder OA, and two men, 42 and 45 years old, both runners, with Achilles tendinopathy for more than 3 months.
Inclusion criteria: chronic pain resistant to conventional treatments, absence of complete lesion documented by ultrasound or MRI, with the goal of a rapid return to competitive activity. Patients with systemic rheumatic diseases, local infections, or anticoagulant therapy were excluded.

Therapeutic protocol:
PRP extraction by centrifugation (5000 rpm × 6 min), final volume 3–4 ml.
Mixed with GUNA Collagen Medical Device (2 ml), re-centrifugation (3400 rpm × 1 min).
A series of three ultrasound-guided injections, spaced 15 days apart.

Procedure: Intra- and periarticular injection with MD SHOULDER + PRP for shoulder OA (40 mm, 23-gauge needle); peri- and intratendinous injection with MD TISSUE + PRP (13 mm, 27-gauge needle) for Achilles tendinopathy.
Assessments included a visual analogue scale (VAS) (0–10), joint range of motion (ROM), and ultrasound examinations with a 3-month follow-up.

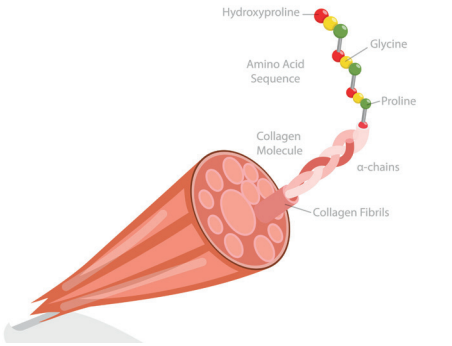

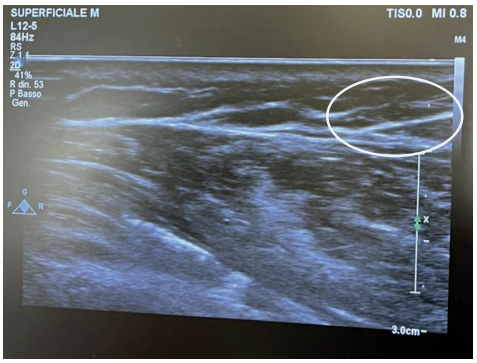

ULTRASOUND-GUIDED INJECTION OF MD SHOULDER (40 MM NEEDLE) FOR OSTEOARTHRITIS AND SUPRASPINATUS TEAR

RESULTS

The patient with shoulder OA reported a reduction in pain (VAS from 7/8 to 0 at the 3-month follow-up) and complete recovery of ROM. The two athletes with Achilles tendinopathy showed similar improvements: pain reduction (VAS from 7/8 to 0), partial normalization of the fibrillar structure, reduction of hypoechogenicity and Doppler signal. All returned to competitive sports. No adverse events were reported, confirming the excellent tolerability of the treatment. The possibility of administering collagen and PRP in the same session simplified the therapeutic process, ensuring greater adherence and reduced overall treatment times compared to separate treatments.

CONCLUSIONS

The simultaneous combination of Guna collagen Medical Devices (Guna S.p.A, Italy) and PRP, in a single ultrasound-guided procedure, has proven safe, well-tolerated, and effective in the treatment of shoulder OA and Achilles tendinopathy. The clinical benefits—pain reduction, functional recovery, and rapid return to competitive activity—are comparable, if not superior, to those described in the literature for the separate use of the two therapies. From a pathophysiological standpoint, collagen appears to promote repair and structural action, while PRP amplifies the regenerative process, resulting in a clinically relevant synergy. Further prospective studies, on larger patient samples and with more extended follow-up, are needed to validate these preliminary results and define standardized protocols. The treatment is doping-free and potentially applicable to a wide range of musculoskeletal disorders, offering new perspectives in regenerative medicine and elite sports.

BIBLIOGRAPHY:

1. Randelli F, Sartori P, Carlomagno C, Bedoni M, Menon A, Vezzoli E, Sommariva M, Gagliano N. The Collagen-Based Medical Device MD-Tissue Acts as a Mechanical Scaffold Influencing Morpho-Functional Properties of Cultured Human Tenocytes. Cells. 2020 Dec 8;9(12):2641.
2. Godek P, Szczepanowska-Wolowiec B, Golicki D. Collagen and platelet-rich plasma in partial-thickness rotator cuff injuries. Friends or only indifferent neighbours? Randomised controlled trial. BMC Musculoskelet Disord. 2022 Dec 20;23(1):1109.
3. Bianco Prevot L, Bensa A, Randelli PS, Filardo G. Cartilage lesions are not the main factor influencing pain and functional impairment in early knee osteoarthritis: a multivariate analysis on intra- and extra-articular factors affecting symptoms in over 200 knees. Bone Jt Open. 2025 Jul 16;6(7):828-835.

52° CONGRESSO NAZIONALE SIMFER
PADOVA 6 | 9 OTTOBRE 2024

THERAPEUTIC OUTCOME IN PATIENTS WITH ROTATOR CUFF INJURY: TREATMENT WITH COLLAGEN INJECTIONS

A.Rocco MD PhD, A. Cardarola MD, Medicina Riabilitativa, INI Grottaferrata (Roma)
INI UOC Grottaferrata Riabilitazione

INTRODUCTION:

A rotator cuff injury is generally associated with tears in the tendon tissue, which may lead to detachment from the bone surface. This type of injury can occur due to various causes, including trauma, improper movements, excessive loading, or direct impact to the shoulder. The most common cause of rotator cuff tears is tendon degeneration resulting from wear and tear over time.
Symptoms include shoulder pain that may radiate to the elbow, restricted joint mobility, reduced function, and possible muscle weakness. Accurate diagnosis is essential to determine the most appropriate treatment.
The purpose of this study was to evaluate the effect of an injectable treatment- 2 ml of collagen (Guna MD-Shoulder)- on tendon and muscle injuries, as assessed by musculoskeletal ultrasound.

MATERIALS AND METHODS:

Fifteen patients with rotator cuff injuries were enrolled in the study following outpatient consultations at the Physical and Rehabilitation Medicine Clinic. Each patient underwent a physical medicine examination and diagnostic tests, including NRS and Constant Scale assessments, laboratory tests (ESR, CRP, complete blood count, electrophoretic proteinogram), and ultrasound evaluation of the affected shoulder.

All patients received peri-tendinous and peri-lesional injections of a 2 ml collagen preparation (Guna MD-Shoulder), guided by ultrasound using the Samsung HS-40 system and power Doppler. The procedure was repeated once a week for 10 consecutive weeks.

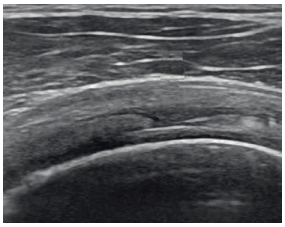

COLLAGEN

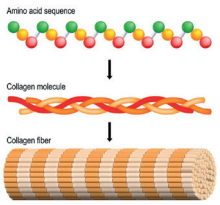

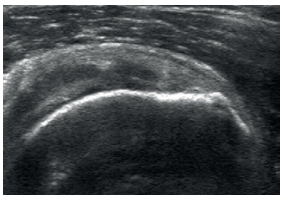

N.	Paziente	NRS iniziale	NRS intermedia	NRS finale
1	A.D.	8	4	2
2	C.R.	7	5	2
3	D.E.	9	7	3
4	F.C.	9	8	2
5	D.T.	8	4	3
6	L.M.	7	7	4
7	O.P.	8	7	7
8	S.G.	9	6	4
9	R.S.	9	4	2
10	L.A.	7	3	2
11	E.S.	8	6	3
12	T.L.	9	7	2
13	A.D.	9	7	0
14	P.O.	7	5	0
15	V.T.	6	4	6
	MEDIA	8	5,733333	2,8

P value and statistical significance:
The two-tailed P value is less than 0.0001
By conventional criteria, this difference is considered to be extremely statistically significant.

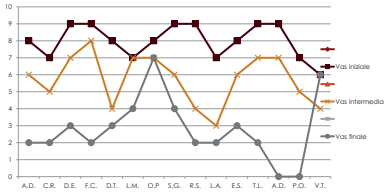

Confidence interval:
The mean of Group One minus Group Two equals 5.14
95% confidence interval of this difference: From 3.97 to 6.31

RESULTS AND CONCLUSIONS:

Patients treated with MD-Shoulder Guna injections showed a statistically significant reduction in pain (NRS), decreased inflammatory markers as observed via power Doppler, and progressive improvement in daily activities, attributed to the restoration of joint function.

Bibliografia:

1.May T, Garmel GM. Rotator Cuff Injury. 2023 Jun 26. In: StatPearls [Internet]. Treasure Island (FL): StatPearls Publishing; 2024 Jan
2.Randelli F, Sartori P, Carlomagno C, Bedoni M, Menon A, Vezzoli E, Sommariva M, Gagliano N. The Collagen-Based Medical Device MD-Tissue Acts as a Mechanical Scaffold Influencing Morpho-Functional Properties of Cultured Human Tenocytes. Cells. 2020 Dec 8;9(12):2641
3.Coombes BK, Bisset L, Vicenzino B. Efficacy and safety of corticosteroid injections and other injections for management of tendinopathy: a systematic review of randomised controlled trials. Lancet. 2010 Nov 20;376(9754):1751-67.

Unità Operativa Complessa di Riabilitazione INI Grottaferrata - Via S. Anna snc
alain.rocco@gruppoini.it

SIOT 2024 ROMA
www.congressosiot.it
107° CONGRESSO NAZIONALE DELLA SOCIETÀ ITALIANA DI ORTOPEDIA E TRAUMATOLOGIA
Roma 29-31 Ottobre Centro Congressi Rome Cavalieri Waldorf Astoria

ULTRASOUND-GUIDED COLLAGEN INJECTABLE THERAPY IN PARTIAL ROTATOR CUFF TEARS (RC)

ANDREA ZAGARELLA[1], BARBARA DEROMEDIS[2], VALENTINA FREZZA[3], FRANCESCO GARUTI[3], ILARIA EMILI[4], PIETRO SIMONE RANDELLI[5]

[1]Head of S.S.Radiodiagnostics Presidio CTO ASST Pini-CTO Milan
[2]Medical Director Orthopaedic Clinic Presidio CTOASST Pini-CTO Milan
[3]School of Specialisation in Radiology University of Milan
[4]Medical Director Radiodiagnostics Presidio CTO ASST Gaetano Pini-CTO Milan
[5]Director U.O.C. Orthopaedic Clinic ASST Pini-CTO Milan

INTRODUCTION:

Rotator cuff disorders (RCD) rank third in prevalence among musculoskeletal conditions. In particular, partial supraspinatus tendon lesions (PSTLs) due to degenerative changes are the most common in individuals over the age of 60. Collagen injections have been shown to potentially counteract tendon degeneration and the progression of partial tears.

MATERIALS AND METHODS:

Twenty patients (10 males and 10 females), aged between 26 and 77 years (median age 63), with PSTLs reporting pain at maximum intensity but with preserved range of motion (ROM) were treated with a cycle of three ultrasound-guided injections of 2 ml MD-Tissue + 2 ml MD-Shoulder, administered approximately 10 days apart. After 3 months, an ultrasound and clinical follow-up evaluation was performed. Changes in pain symptoms were assessed using the Visual Analogue Scale (VAS), and the significance of the variation was analyzed using the T-test (p value < 0.05).

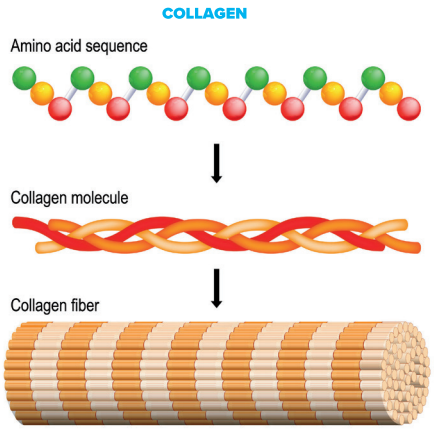

RESULTS:

Ultrasound examination revealed 1 intratendinous lesion, 3 articular-sided lesions, and 16 bursal-sided lesions. All patients reported a significant reduction in pain symptoms three months after the end of the injection cycle, with a mean pre-treatment VAS score of 7.5 and a post-treatment score of 3.2 ($p < 0.001$).

DISCUSSION:

Ultrasound-guided collagen injections for degenerative RCD tendinopathy represents an innovative, minimally invasive therapeutic approach capable of reducing pain symptoms and overall improving joint function and quality of life in patients with partial rotator cuff tears. In fact, it has been shown that local injectable administration of collagen promotes tendon fiber homeostasis and the repair process.

CONCLUSION:

In our experience, a cycle of collagen injections in cases of PSTLs can significantly reduce pain symptoms. The use of ultrasound-guided technique also allows for precise administration at the site of the rotator cuff lesion. Ultrasound evaluation, as a first-line imaging tool, enables the identification of patients eligible for this conservative treatment, proving to be a valid therapeutic alternative for patients with partial tendon tears, especially for those who are not eligible for surgical treatment.

BIBLIOGRAPHY:
1. Randelli, P., Bak, K. & Milano, G. State of the art in rotator cuff repair. Knee Surg Sports Traumatol Arthrosc 23, 341–343 (2015)
2. Randelli F, Menon A, Giai Via A, Mazzoleni MG, Sciancalepore F, Brioschi M, Gagliano N. Effect of a Collagen-Based Compound on Morpho-Functional Properties of Cultured Human Tenocytes. Cells. 2018 Dec 6;7(12):246.
3. Randelli F, Sartori P, Carlomagno C, Bedoni M, Menon A, Vezzoli E, Sommariva M, Gagliano N. The Collagen-Based Medical Device MD-Tissue Acts as a Mechanical Scaffold Influencing MorphoFunctional Properties of Cultured Human Tenocytes. Cells. 2020 Dec 8;9(12):2641.

12° I.S.Mu.L.T. Congress
12-13 Aprile 2024 - Roma

THERAPEUTIC OUTCOME IN PATIENTS WITH ROTATOR CUFF INJURY: INJECTION TREATMENT WITH COLLAGEN

A. Rocco MD PhD, A. Cardarola MD, Physical rehabilitation Hospital Unit , INI Grottaferrata (Rome)

INTRODUCTION:

Rotator cuff injury is generally associated with lacerations or tears of the tendon tissue that can cause detachment from the bone surface. This type of injury can occur for various reasons, including traumatic events, incorrect movements, excessive loads or impact on the shoulder. The most common cause of a cuff tear is degeneration of the tendon tissue, caused by wear of the tendons over time. Symptoms of rotator cuff injury include shoulder pain that can radiate to the elbow, limitation of joint movement, reduced function and possible muscle weakness. It is essential to diagnose this condition correctly in order to determine the most appropriate treatment.
The aim of this work was to evaluate the effect of injection treatment with 2 ml collagen (Guna MD-TISSUE) at the tendon and muscle lesions, revealed by muscular- skeletal ultrasound.

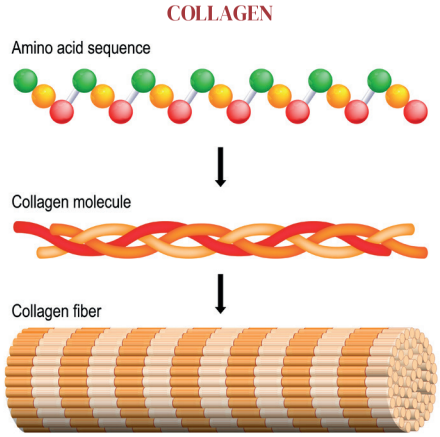

METHODS:

Three patients (aged 52, 58 and 80) with rotator cuff lesions who came to our attention through visits at the Outpatient Physical Rehabilitation Medicine Clinic were enrolled.
A Medical examination and diagnostic investigations (NRS assessment scale, Constant Scale, laboratory tests, ESR, CRP, haemochromocytometric, electrophoretic protidogram, ultrasound evaluation of the injured shoulder) were performed for each patient.
All patients underwent ultrasound-marked peri-tendon and peri-lesion injection with a Samsung HS-40 system and power Doppler of 2 ml of the class III medical device collagen (GUNA MD-TISSUE) using a 25-mm long, 25 Gauge needle.
The procedure was repeated once a week for 5 consecutive weeks.

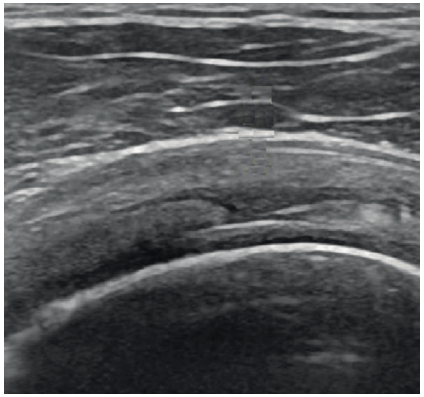

Before treatment

RESULTS:

Patients who underwent injections of GUNA MD-TISSUE showed, statistically, a significant reduction in pain from 8 to 5 (NRS), a reduction in inflammatory parameters, evidenced by power doppler, and a progressive recovery to the performance of daily living activities, thanks to restoration of the functional component of the treated joint.

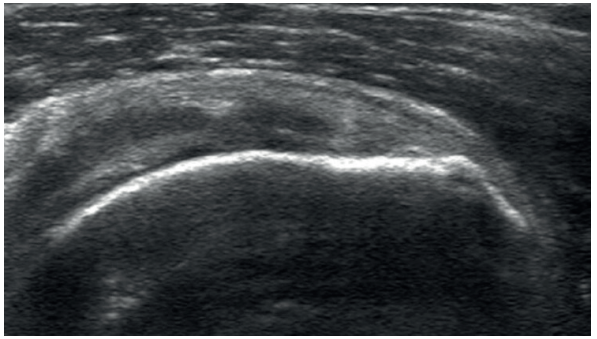

After treatment

CONCLUSIONS:

Collagen MD TISSUE injections have proven to be a safe and effective therapy compared to other injection therapies such as corticosteroids which have a short-term action only on acute pain with the risk of damage to tendon structures.
Collagen, acting as an extracellular matrix bio-scaffold on connective tissues that have suffered damage or wear, stimulates the synthesis of new collagen, repairs and regenerates tissues leading to functional healing. It is a new, cost-effective and regenerative therapeutic solution.

REFERENCES:

1. May T, Garmel GM. Rotator Cuff Injury. 2023 Jun 26. In: StatPearls [Internet]. Treasure Island (FL): StatPearls Publishing; 2024 Jan
2. Randelli F, Sartori P, Carlomagno C, Bedoni M, Menon A, Vezzoli E, Sommariva M, Gagliano N. The Collagen-Based Medical Device MD-Tissue Acts as a Mechanical Scaffold Influencing Morpho-Functional Properties of Cultured Human Tenocytes. Cells. 2020 Dec 8;9(12):2641
3. Coombes BK, Bisset L, Vicenzino B. Efficacy and safety of corticosteroid injections and other injections for management of tendinopathy: a systematic review of randomised controlled trials. Lancet. 2010 Nov 20;376(9754):1751-67.

12° I.S.Mu.L.T. Congress
12-13 Aprile 2024 - Roma

I.R.C.C.S. Ospedale San Raffaele
Gruppo San Donato

TREATMENT OF SHOULDER INSTABILITY IN A YOUNG FEMALE WITH EHLERS-DANLOS SYNDROME

Yen Tao-Yu MS[1], Cimino Paolo MD[1], Padul Jeffrey David MD[1], Rocca Gregorio MD[1] Giranio Giorgia MD[1], Emedoli Daniele PT[1], Iannacone Sandro MD[1], Brugliera Luigia MD PhD[1]
Affiliations: [1]Department of Rehabilitation and Functional Recovery, IRCCS San Raffaele Scientific Institute, Milan, Italy

INTRODUCTION:

The Ehlers-Danlos syndrome (EDS) is a group of diseases majorly affecting collagen formation. The symptoms and severity vary from patient to patient, including skin hyperelasticity, joint hypermobility, and collagen malformation causing soft tissue disorder.
According to the specific diagnostic criteria issued by the Ehlers–Danlos Society in 2017, EDS can be subdivided into 13 types: Classical EDS (cEDS, I), Hypermobile EDS (hEDS, III), Vascular EDS (vEDS, IV), Kyphoscoliosis EDS (kEDS, VI), Arthrochalasia EDS (aEDS, VII A&B), Dermatosparaxis EDS (dEDS, VII C), etc. Among these subtypes, the Hypermobile EDS (hEDS, III) is one of the most common in patients.
Joint hypermobility means the joint(s) of the patients can reach an incredible action compared to the average, caused by ligament and tendon weakness due to collagen malformation. This symptom appears widely in many subtypes of EDS. To keep normal motor function, the weak tendons and ligaments crave further energy and materials to maintain joint stability. Therefore, it raises inflammation, pain, and dysfunction at or around the joints and, in the later phase, globally. Patients suffer not only frequent joint dislocation and sub-dislocation but also general weakness and tiredness.
Up to now, there is no disease-specific treatment for any EDS subtypes. To the present, the most applicable treatment is the multi-discipline symptom and supportive treatment.
Since collagen is the fundamental component of connective tissue, and Ehlers-Danlos Syndrome is a disease with the changes in the genes affecting the structure and function of collagen and related connective tissue proteins, the use of injection and oral administration of collagen may bring about better symptom management by its mechanical properties as a bioscaffold of the extracellular matrix to stabilise the articulation.
This clinical case report demonstrates the efficacy of collagen-based treatment.

COLLAGEN FORMATION

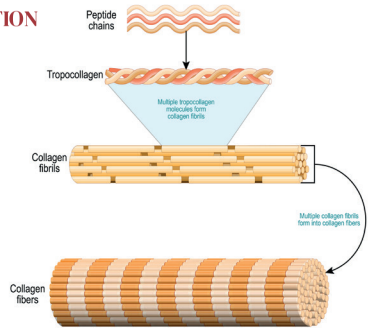

CLINICAL CASE:

A 29-year-old female came to our physiatric outpatient clinic with long-term frequent sub-dislocations and dislocations on the mandibular and shoulders.
In 2018, she had her first episode of shoulder dislocation while she was trying to carry a heavy suitcase in the airport. She used to be sporty, fast walking three times and amateur badminton twice per week.
In 2022 summer, she had sub-dislocation on the shoulders bilaterally during her work. Since then, she has suffered from multiple sub-dislocations and dislocations on the shoulders. Later in autumn, she experienced numerous monolateral mandibular sub-dislocations and dislocations.
Days before Christmas in 2022, she was diagnosed with Ehlers-Danlos Syndrome with a genetic test, classified as Hypermobile type.
In April 2023, she underwent a physiatric visit for severe bilateral shoulder, worse on the left to the right, instability due to Ehlers-Danlos Syndrome (1).

The treatment was indicated as follows:

- Ten times of physiotherapy sessions:
  - Twice a week, for 5 weeks
  - Exercises to stabilize the scapula and rebuild the shoulder's muscular balance by strengthening the muscles.
  - Improve the joint control to achieve the full recovery of the joint function.
- Ten times of collagen injections:
  - Intra-articular once a week for 5 weeks; peri-articular once a week for 5 weeks (Guna MD-Shoulder) (2)
- Compliments supply:
  - 1 flacon per day orally with collagen (5,000 mg), hyaluronic acid (200 mg), vitamin C and Manganese.
- Pharmacological treatment:
  - Etoricoxib 60 mg 1 tablet daily for 2 weeks

A bilateral shoulder ultrasound was requested and carried out one week after the visit, with findings of:

BILATERAL SHOULDER ULTRASOUND:
Parts linear probe, highlighted, in correspondence with the left acromioclavicular joint, a hint of acromioclavicular misalignment due to a very slight cranial displacement of the lateral end of the clavicle.
On the left, the head of the humerus is partially misaligned concerning the glenoid cavity.
On the right, thinned and non-homogeneous infraspinatus tendon in the absence of full-thickness lesions.

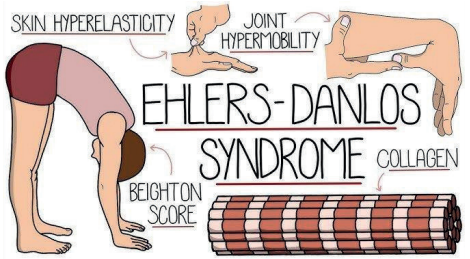

RESULTS:

The entire treatment was well tolerated (NRS from 10 to 3).
The scales at the end of therapy show the following scores:

NRS (pre)

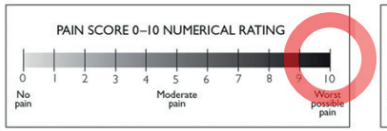

NRS (post)

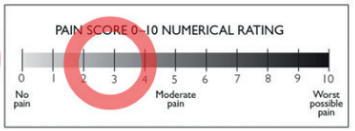

CONCLUSIONS:

The combination of collagen (oral and intra-articular/peri-articular) and targeted physiotherapy shows effectiveness in pain management and recovering shoulder joint stability. This injective collagen protocol could be a novel, valid and well tolerated therapy, without side effect, for this type of patients that needs a safety management.

REFERENCES:

1. Management of shoulder instability in hypermobility-type Ehlers-Danlos syndrome Samuel E. Broida, BS, Aidan P. Sweeney, MS, Michael B. Gottschalk, MD, Eric R. Wagner, MD, MS
2. COLLAGEN STRUCTURE AND STABILITY Matthew D. Shoulders1 and Ronald T. Raines1,2 Ronald T. Raines: raines@biochem.wisc.edu

POSTER NO. 51

SIMFER
SOCIETÀ ITALIANA DI MEDICINA FISICA E RIABILITATIVA
The Italian Society of Physical and Rehabilitation Medicine

CALCIPHIC TENDINOSIS: A novel injectable collagen-based therapeutic solution.

***Mirko Mutti*[1]**

1. Physical Medicine and Rehabilitation - Centro Polispecialistico Pacini Milan

Centro Polispecialistico Pacini s.r.l.

Introduction

Calcific tendinosis is the chronic suffering of a tendon, characterised by the degeneration of the normal tendon structure. Calcium deposits reduce the elasticity and mobility of the tendons involved, which, by becoming stiffer, are more prone to become inflamed when stressed.
The aim of this case report is to prevent tissue damage in the shoulder by injectable therapy with collagen, as an alternative to other conservative therapies such as PRP (more investigative and expensive) or non-conservative therapies such as surgery.
Collagen is the most abundant protein present in the connective tissue that surrounds and protects the peri-articular compartment, such as tendons and ligaments. Its exogenous supplementation by injection strengthens and repairs damaged structures, giving greater elasticity and resistance.

Materials and Methods

One 58-year-old patient suffering from calcific tendinosis of the right shoulder (supraspinatus and long head of the biceps) with functional limitation and chronic stiffness in the investigated planes of movement was treated. A musculotendinous ultrasound was performed before and after the injectable treatment. Prior to starting the collagen injection cycle, the patient was treated with a focal shock wave cycle.
A course of 5 injections of MD-TISSUE was performed (1 injection per week for 5 weeks), using a 25 mm 26G needle in the peri-lesional site.
Pain was assessed by means of a VAS scale, initial value (T0) 8 and final value (T1) 1-2.
During the treatment, a progressive subjective/clinical improvement of the pain symptoms and mobility of the right shoulder associated with a physiokinesitherapy cycle with stretching was observed. MD-TISSUE is a class III medical device that has a mechanical scaffold effect and an antioxidant role due to the presence of its excipients (vitamin C/B1, B2, B6 and magnesium gluconate).
Follow-up was performed at 3 months with reported stable VAS 1-2 pain and no reported anti-inflammatory intake. The follow-up at 6 months confirmed the absence of pain symptoms.

Figure 1:*Image of calcific shoulder tendinosis*

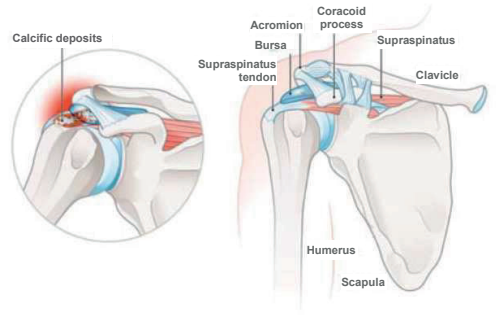

Figure 2:*Triple helix collagen*

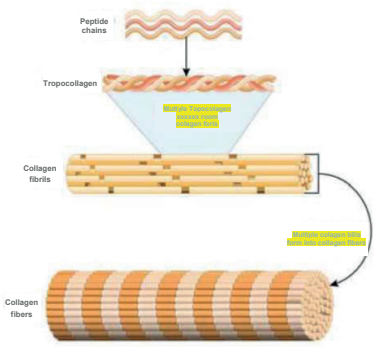

Results

MD-TISSUE enabled an improvement in tendon fibre quality and improved tendon mobility in sliding, a significant reduction in pain and an improvement in joint mobility associated with physiokinesitherapy.
The efficacy of collagen meant that there was no need for cortisone injection. The benefit of the latter must be weighed against the risk of a possible delay in the healing process and is only useful in cases of acute and not chronic pain, as was the case with this patient.

Conclusions

Collagen-injection treatment promoted homeostasis, remodelling and tissue repair by acting as an active scaffold in the extracellular membrane. It was able to repair the damage, improving the functionality of the compromised structures.
GUNA MD-TISSUE is a regenerative, restorative, useful, safe, easy-to-use, side-effect-free and cost-effective therapeutic treatment compared to other injectable therapies. It may prove to be a treatment that can be combined with a course of instrumental treatment with focal shock waves. The latter can reduce calcification, while collagen can improve and restore tissue integrity and realign fibres.

References

- De Carli, A., Pulcinelli, F., Rose, G. D., Pitino, D., & Ferretti, A. (2014). Calcific tendinitis of the shoulder. Joints, 2(3), 130-136. https://doi.org/10.11138/jts/2014.2.3.130
- Randelli F, Menon A, Giai Via A, et al, Effect of a Collagen-Based Compound on Morpho-Functional Properties of Cultured Human Tenocytes. Cells. 2018 Dec 6;7(12):246.
- Randelli F, Sartori P, Carlomagno C, Bedoni M, Menon A, Vezzoli E, et al. The Collagen-Based Medical Device MD-Tissue Acts as a Mechanical Scaffold Influencing Morpho-Functional Properties of Cultured Human Tenocytes. Cells. 2020 Dec 8;9(12):2641.

SPINE – LUMBAR SPINE

POSTER NO.
76

SIMFER
SOCIETÀ ITALIANA DI MEDICINA FISICA E RIABILITATIVA
The Italian Society of Physical and Rehabilitation Medicine

COMPARISON OF THE COMBINED INTRAMUSCULAR INJECTION TREATMENT OF OZONE/COLLAGEN THERAPY AND THE INTRAMUSCULAR INJECTION TREATMENT OF OZONE THERAPY FOR CHRONIC LOW BACK PAIN DUE TO DISCOPATHY

Liliana Sgarbi[1], Manuela De Pascalis[1], Susanna Mulas.[1]

1 U.O.C. FBF Specialist Rehabilitation, Department of Medicine ASST FBF - SACCO, Piazza Principessa Clotilde 3, Milan, Italy.

Introduction Any innervated structure of the spine can cause low back pain: muscles, ligaments, the dura mater, nerve roots, zygapophysial joints, the fibrous annulus and the fascial system.
The rationale for using ozone therapy to treat chronic low back pain in discopathies is based on the combination of anti-inflammatory action and acceleration of the dehydration process of the disc's cartilage tissue.
The fascial system, i.e. the collection of all collagen-based tissues, represented by a three-dimensional network throughout the body, is also involved in the aetiology of pain.
The deep thoraco-abdominal fascia is involved in chronic lumbar symptoms: microstructural changes in collagen and structural changes in connective tissue are described.
Collagen administered by local intramuscular injection provides the necessary substrate to positively remodel the connective tissue that makes up the thoraco-abdominal fascia.
The aim of the study is to highlight the complementary nature of the two therapies when it comes to controlling lower back pain symptoms in discopathies.

Materials and Methods Twenty male and female patients, aged between 38 and 79 years, with an average age of 58 years were enrolled in the study.
Patients with lower back pain with for more than six months investigated with an MRI of the lumbosacral spine and evidence of a discopathy were included in the study.
Exclusion criteria: acute radicular signs in the lower limbs; active and/or ongoing oncological pathologies, cognitive impairment and patients reluctant to provide the informed consent. Inclusion criteria: A lumbosacral MRI with an evidence of disc herniation or multiple disc protrusions, persistent lower back pain for at least six months, NSAID and painkiller therapy that has been discontinued for at least two weeks, cortisone therapy that has been discontinued for at least two months.

Figure 1: *injection of collagen.*



Table 1: *Evaluation and follow-up of patients with ROM, VAS and the Roland-Morris questionnaire.*

Patient assessment and follow-up	
T0	Before the first injection
T1	After the last injection
T2	One month after the last injection

The patients were divided into two groups: group A (OT only) and group B (OT + collagen + Hamamelis). All patients (A+B) were treated with paravertebral intramuscular injections of O2O3 at a concentration of 10 ug. The total volume injected in each treatment corresponds to 20ml split into four injection points (5ml per point). Needle used: 23G 32 mm. All patients were treated twice a week for a total of 8 consecutive injection treatments. Twenty minutes after the lumbar IM administration of O2O3, patients in group B were subjected to an intramuscular injection of collagen + Hamamelis, 1 2-ml vial split over 4 injection sites. Needle used: 27G 19 mm.

Results The patients in group B described greater control over the pain symptoms (VAS scale) and joint recovery at the end of the treatment cycle, and a greater stability of the results obtained in the control at one month than in group A.

Figure 2A

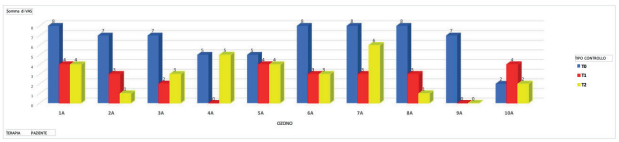

Figure 2B

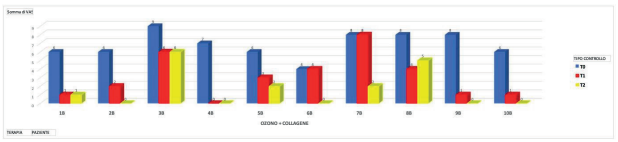

Figure 2C

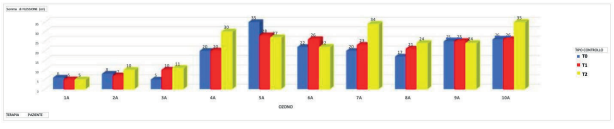

Figure 2D

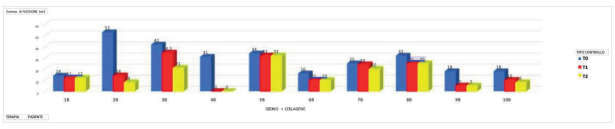

Figure 2: *Graphic representation of results; reduction in VAS in the two groups of patients (Fig. 2A and 2B) and after combined OT + collagen therapy (Fig. 2B); greater consolidation of the results obtained in the one-month follow-up after the end of treatment with combined OT + collagen therapy (Fig. 2B). Greater joint recovery with the combination therapy and further improvement at the one-month follow-up (Fig. 2D) compared to the group treated with OT alone (Fig. 2C).*

Conclusions

The ultrasound-observed connective tissue disorganisation and microstructural alterations of the collagen tissue can be treated by stimulating a positive remodelling of the tissue constituting the thoraco-abdominal fascia. The administration of collagen and Hamamelis Virginiana injections provides the necessary substrate for remodelling and acts synergistically with ozone therapy with improved expected results.

References

1. Meccanismi d'azione dell'ozono Valdenassi L. University of Pavia – SIOOT 2012
2. Randelli F, Menon A, Giai Via A, et al, Effect of a Collagen-Based Compound on Morpho-Functional Properties of Cultured Human Tenocytes. Cells. 2018 Dec 6;7(12):246.
3. Randelli F, Sartori P, Carlomagno C, Bedoni M, Menon A, Vezzoli E, et al. The Collagen-Based Medical Device MD-Tissue Acts as a Mechanical Scaffold Influencing Morpho-Functional Properties of Cultured Human Tenocytes. Cells. 2020 Dec 8;9(12):264

ELBOW

SICM
Società Italiana di Chirurgia della Mano
63° CONGRESSO NAZIONALE
SOCIETÀ ITALIANA CHIRURGIA DELLA MANO
2-4 OTTOBRE 2025 - MILANO

ULNAR NERVE SYNDROME AT THE ELBOW IN A VIOLINIST RESISTANT TO CONVENTIONAL THERAPIES

JACOPO GIOVANNI PAOLO ACQUATI LOZEJ
Director of Orthopedics and Traumatology UOC, Foundation IRCCS Ca' Granda Ospedale Maggiore Policlinico, Milan

SOFIA COMITANI
Resident Doctor, Physical and Rehabilitation Medicine, Foundation IRCCS Ca' Granda Ospedale Maggiore Policlinico, Milan

INTRODUCTION

Ulnar nerve syndrome at the elbow is a condition caused by compression or irritation of the ulnar nerve as it courses through the cubital canal. It presents with paresthesia and pain, particularly affecting the fifth and fourth fingers of the hand, and can compromise function, especially in subjects requiring manual dexterity, such as musicians.
Treatment options are generally instrumental, pharmacological, or surgical. Collagen injections have a rationale for its mechanical effect and remodeling of the perineural extracellular matrix, proving to be a cost-effective and safe therapy.

MATERIALS AND METHODS

The case report presented is a 13-year-old professional violinist suffering from ulnar nerve compression syndrome at the right elbow. In 2023, he entered our clinic with recurrent symptoms resistant to conventional therapy (shock waves, oral cortisone, and NSAIDs). At the end of preparation sessions for a concert, disabling pain and paresthesia persisted with Tinel++. Musculotendinous ultrasound showed edema along the course of the ulnar nerve in the right elbow without signs of dislocation from the cubital canal. The patient underwent electromyography, which confirmed compression neuropathy of the ulnar nerve in the right elbow. Given the patient's need to continue his artistic training and his young age, surgery was ruled out in favor of conservative treatment with collagen injections near the perineurium, under ultrasound guidance with a 13 MHz linear probe, 2 ml of MD-NEURAL (Guna S.p.A., Milan, Italy) administered three times 10 days apart, after obtaining the patient's parental consent. Free mobilization of the elbow was permitted at the end of the procedure.

RESULTS

At the end of ultrasound-guided infiltration therapy with MD-NEURAL, the patient no longer presented paraesthesia symptoms, and a follow-up ultrasound examination (performed by the same operator with a 13 MHz linear probe) 40 days after the start of therapy revealed that the perineural edema had been reabsorbed.

CONCLUSIONS

The use of MD-NEURAL appears to be a valid therapeutic option for the treatment of ulnar nerve compression syndromes at the elbow.

COLLAGEN

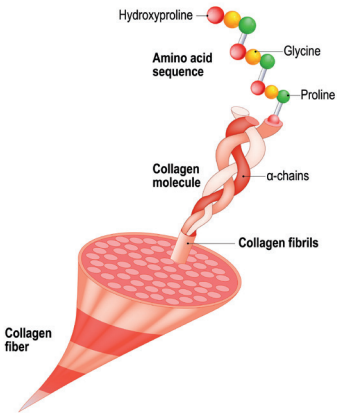

CUBITAL TUNNEL SYNDROME
(ULNAR NERVE COMPRESSION)

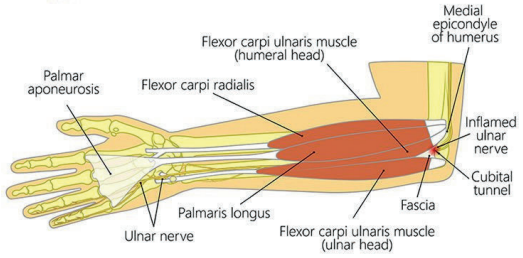

NERVES OF THE ARM

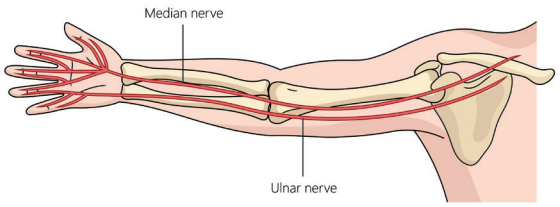

BIBLIOGRAPHY:

1. Li Xiaolan et al. The application of collagen in the repair of peripheral nerve defect Frontiers in Bioengineering and Biotechnology Volume 10 – 2022
2. Randelli et al. Effect of a Collagen-Based Compound on Morpho-Functional Properties of Cultured Human Tenocytes. Cells 2018 Dec 6;7(12):246
3. Randelli et al. The Collagen-Based Medical Device MD-Tissue Acts as a Mechanical Scaffold Influencing Morpho-Functional Properties Cells 2020 Dec ;9 (12): 2641

SIMFER
SOCIETÀ ITALIANA DI MEDICINA FISICA E RIABILITATIVA
The Italian Society of Physical and Rehabilitation Medicine

POSTER N. 53

53° CONGRESSO NAZIONALE SIMFER
RICERCA E INNOVAZIONE IN MEDICINA FISICA E RIABILITATIVA
NAPOLI
23 | 26 NOVEMBRE 2025



TREATMENT OF MEDIAL EPICONDYLITIS WITH COLLAGEN INJECTIONS: A CASE SERIES

Cristiano Fusi Head of Physical Rehabilitation Department, San Martino Clinic Malgrate, Lecco
Ennio Lopresti Physical Rehabilitation Department, San Martino Clinic Malgrate, Lecco

CLINICA SAN MARTINO
Eccellenza Accessibile.

INTRODUCTION

Medial epicondylitis (ME), also called golfer's elbow, is a tendinopathy of the medial flexor tendon of the elbow caused by overload or overuse. It is a degenerative insertional tendinopathy that affects the tendons of the wrist and finger flexor muscles at the insertion level on the medial epicondyle of the humerus. Repetitive activity leads to recurrent micro-tears within the tendon and subsequent tendinosis. As the tendon sustains repetitive micro-tears, a remodeling of the collagen fibers and an increase in the mucoid ground substance occurs. Subsequently, the collagen strength decreases, leading to increased fragility, scar tissue formation, and tendon thickening. ME, although less common than lateral epicondylitis, represents 10% to 20% of all cases of epicondylitis. The prevalence is 0.4% of the population. It is more prevalent among people aged 45 to 64, more in women than men, and in some professions (manual workers, athletes such as tennis players, golfers, and pitchers), prevalence can reach 3.8-8.2%. Three out of four cases involve the dominant arm. Risk factors include smoking, obesity, diabetes, and work activities involving repetitive gripping or pronation of the wrist for more than 2 hours a day. MRI or ultrasound can assess thickening of the common flexor tendon sheath, identify any intra-articular or soft-tissue complications, and ulnar collateral ligament injuries.
Conservative therapy includes oral and topical nonsteroidal anti-inflammatory drugs, paracetamol, topical nitroglycerin patches, ice, physical therapy, dry needling, transcutaneous electrical stimulation, iontophoresis, short-term cortisone injections, and PRP.
The rational for the use of collagen injections is the presence of collagen fiber disorganization and tendon degeneration, and the effect of collagen on tissue remodeling and restoration of the extracellular matrix (ECM), providing structural support as a bioscaffold. Used alone or in synergy with strengthening exercises or shock waves, collagen injections can reduce the need for anti-inflammatory drugs or cortisone injections.

COLLAGEN SYNTHESIS

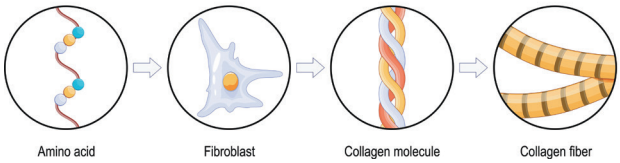

GOLFER'S ELBOW
(MEDICAL EPICONDYLITIS)

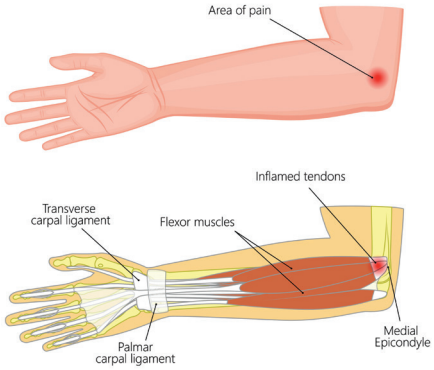

MATERIALS AND METHODS

Three patients were treated. They had a positive muscle-tendon ultrasound for moderate/severe medial epicondylitis at the physical therapy visit:

- Patient 1: medial epicondylitis of the right elbow. Female, 56, smoker, office worker. Diagnosed approximately one year earlier with right breast cancer, treated with quadrantectomy, sentinel lymph node removal, and radiotherapy. VAS = 7.
- Patient 2: right elbow medial epicondylitis. Male, 32, athletic, good general health. He cycles for an hour and a half a day for work: already treated with two cycles of focused shockwave therapy without benefit. VAS = 6.
- Patient 3: left elbow medial epicondylitis. Male, 21, amateur tennis player, good general health. Simultaneously with the infiltrative treatment, he underwent a cycle of focused shockwave therapy (once a week for 3 weeks) at another facility. VAS = 5.

VAS assessed at T0 (start of treatment) and T1 (4 weeks after the end of treatment). A follow-up musculotendinous ultrasound was performed approximately one month after the end of treatment.
During the injection treatment, patients underwent two weekly sessions for 5 weeks of physiotherapy with soft tissue mobilization, passive and active-assisted stretching, neurodynamic techniques, and subsequent active re-education and functional strengthening.
The injection protocol included one ultrasound-guided injection per week for 4 weeks with 2 ml of MD-TISSUE collagen medical device (Guna S.p.A., Milan, Italy)..

RESULTS

The final medial VAS was 2 (between 3 and 1). Nearly complete recovery of function, reduced pain, and almost complete recovery of range of motion and muscle strength were noted. Follow-up ultrasound showed a marked reduction in the inflammatory component, with preserved thickness and within normal limits

CONCLUSIONS

Injection therapy with MD-TISSUE played a key role in stimulating tendon regeneration by providing structural and biochemical support for the repair of damaged tendon ECM and promoting collagen remodeling, shifting from a disorganized pattern (collagen type III) to a more functional one (collagen type I), acting as a bioscaffold. Furthermore, by modulating the activity of fibroblasts and tenocytes, it has a restorative and regenerative effect. Therefore, the use of MD-TISSUE collagen medical device has proven to be a valid and cost-effective therapeutic option in the treatment of ME, both as a complementary approach and as a possible alternative to physical therapies such as shock waves, resulting in faster recovery from the symptoms of medial epicondylitis.

BIBLIOGRAPHY:

1. Kiel J, Kaiser K. Golfers Elbow. 2023 Jun 26. In: StatPearls [Internet]. Treasure Island (FL): StatPearls Publishing; 2025 Jan–.
2. Reece CL, Li D, SUSMARSKI AJ. Medial Epicondylitis. 2024 May 2. In: StatPearls [Internet]. Treasure Island (FL): StatPearls Publishing; 2025 Jan–.
3. Randelli F, Sartori P, Carlomagno C, Bedoni M, Menon A, Vezzoli E, Sommariva M, Gagliano N. The Collagen-Based Medical Device MD-Tissue Acts as a Mechanical Scaffold Influencing Morpho-Functional Properties of Cultured Human Tenocytes. Cells. 2020 Dec 8;9(12):2641.

SICM Società Italiana di Chirurgia della Mano
La chirurgia della mano: convergenze di culture diverse
62° CONGRESSO NAZIONALE SOCIETÀ ITALIANA CHIRURGIA DELLA MANO
ROMA 14-16 NOVEMBRE 2024

COL 1 ULTRASOUND-GUIDED INJECTIONS IN TENDINOPATHY LE: CASE SERIES

DR. PIER LUIGI BONUCCI
Hesperia Hospital – Modena

DR. EMANUELE GERACE
Ospedale Maggiore ASST – Cremona

DISCUSSION

Lateral epicondylitis (LE) is a common painful syndrome of the elbow, due to tendinopathy of the common extensor tendon at the lateral epicondyle of the humerus. It is a chronic inflammatory condition caused by repeated microtrauma and excessive overload of the extensor carpi radialis brevis muscle. Conservative treatment of LE includes rest, physical therapy, braces, patches, NSAIDs, shockwave therapy (ESWT), laser, and injections. The efficacy of injectable treatments is variable and presents some challenges. For example, corticosteroids are useful in the short term but have little to no effectiveness in the long term, whereas PRP or autologous stem cells are costly and difficult to use.
A new alternative solution in the management of LE is COL1, which, in addition to being economically advantageous, allows for tissue remodeling. The aim of this study was to evaluate the efficacy of COL1 injections in patients with chronic LE tendinopathy of the elbow, in terms of pain reduction and functional improvement.

COLLAGEN

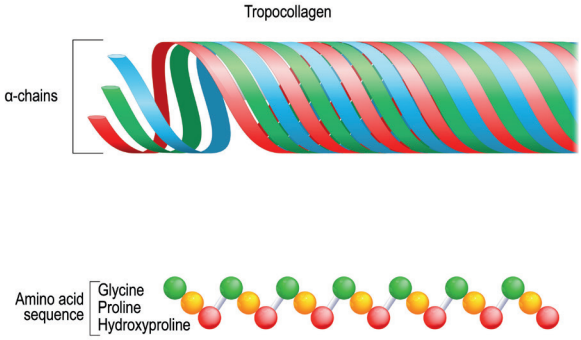

MATERIALS AND METHODS

Twenty patients were enrolled (2 professional tennis players, 5 professional padel players, 3 weightlifting athletes, 10 manual laborers handling heavy loads) with chronic lateral extensor tendinopathy, evaluated by ultrasound and the PRTEE (Patient Rated Tennis Elbow Evaluation) questionnaire.

The patients were treated with cycles of 5 ultrasound-guided injections at weekly intervals. Intratendinous injections of collagen (MD-TISSUE Guna 2 ml) were performed.

Two patients did not respond to collagen injection treatment and underwent surgery; both were professional athletes playing padel and tennis, respectively.

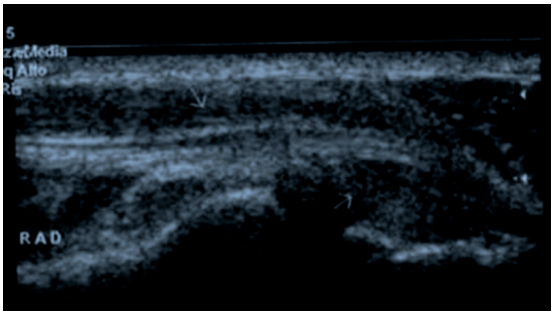

Ultrasound of the right elbow of a patient with lateral epicondylitis

RESULTS

After the cycle of injections, all patients reported a reduction in pain (assessed with a VAS scale from 9 to 0), recovery of functionality, return to play and sports activities.

Follow-ups were conducted at 1, 3 and 6 months through clinical evaluation and ultrasound. There was strong evidence ($p<0.001$) of a statistically significant main effect on multiple clinical observations. Ultrasound showed an improvement in the structural integrity of the tendon.
Collagen MD-TISSUE injected into the intra-tendinous site acted on the degeneration of tendon fibers, stimulating the synthesis of new collagen, restoring the tendon structure and avoiding the need for surgery in most treated patients.

CONCLUSIONS

Collagen is one of the new regenerative therapeutic solutions. It acts as a scaffold for the extracellular matrix (ECM) on damaged or worn connective tissues, stimulates the synthesis of new collagen, repairs/regenerates tissues leading to functional healing, and allows for a quicker return to sports activities.

BIBLIOGRAPHY:

1. Randelli F, Menon A, Giai Via A, Mazzoleni MG, Sciancalepore F, Brioschi M, Gagliano N. Effect of a Collagen-Based Compound on Morpho-Functional Properties of Cultured Human Tenocytes. Cells. 2018;7(12):246
2. Karabinov V, Georgiev. Lateral epicondylitis: New trends and challenges in treatment. WJO 2022;13(4):354-364
3. Corrado B., Mazzuoccolo G., Liguori L., Chirico V.A., Costanzo M., Bonini I. Treatment of Lateral Epicondylitis with Collagen Injections: a Pilot Study MLTJ 2019 9(4):584-589

ISOKINETIC MEDICAL GROUP
FOOTBALL MEDICINE
BRIDGING SCIENCE AND PRACTICE
FIFA | MEDICAL CENTRE OF EXCELLENCE
CÍVITAS METROPOLITANO STADIUM
25th, 26th, 27th, May 2024 • MADRID, Spain



ULTRASOUND-GUIDED INJECTIONS OF COLLAGEN IN TENDINOPATHY: A CASE SERIES

Pier Luigi Bonucci
Orthopedic Surgery and Hand Surgery Department Hesperia Hospital, Modena, Italy

INTRODUCTION AND PURPOSE:

Lateral epicondylitis (LE), also known as tennis elbow, is a frequent painful elbow syndrome due to tendinopathy of the common extensor tendon at the lateral epicondyle of the humerus. It is a chronic inflammatory condition caused by repeated micro-traumas and excessive overload of the extensor carpi radialis brevis muscle.
It affects approximately 1-3% of the population and is frequent in racket sports (e.g., tennis, squash), gymnastics, fitness, and weight lifting. Artists, musicians, electricians, mechanics and other professions that require frequent and repeated movements of the wrists and elbow are also affected.
Lateral epicondylitis is one of the main causes of absence from work and poorer performance by athletes.
Conservative treatment of LE includes: rest, physical therapy, braces, patches, NSAIDs, shock waves (ESWT), laser, injection therapy (corticosteroids, hyaluronic acid, botulinum toxin, PRP, autologous stem cells). The effectiveness of injection treatments is variable and they present some critical issues. For example, corticosteroids are useful in BT, but have little or no effectiveness in LT, while PRP or autologous stem cells are expensive and difficult-to-use methods.
A new alternative solution in LE management is collagen, which, besides being cost-effective, allows tissue remodelling. A 2018 study by Randelli et al. (16) demonstrated the biological rationale, according to which collagen can induce the proliferation and migration of tenocytes, thus promoting tendon repair.
The aim of this study was to evaluate the effectiveness of collagen injections in patients with chronic LE tendinopathy of the elbow (between 2022 and 2023), in terms of pain reduction and improvement of function.

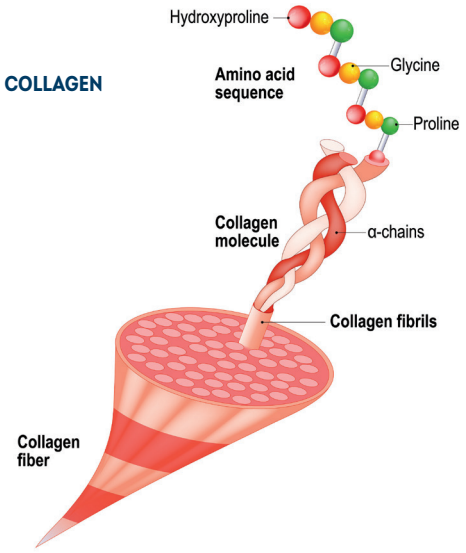

METHODS:

Twenty patients (2 professional tennis players, 5 professional padel players, 3 weightlifting athletes, 10 heavy manual workers) with chronic lateral extensor tendinopathy, evaluated by ultrasound and PRTEE (Patient Rated Tennis Elbow Evaluation) questionnaire, were enrolled.
Patients were treated with cycles of 5 ultrasound-guided injections at weekly intervals.
Intratendinous collagen injections (MD-TISSUE Guna 2 ml) were performed using a 55 mm, 26 Gauge needle.
Two patients did not respond to treatment with collagen injections and underwent surgery; both were professional athletes who play Padel and tennis, respectively.
One patient was surgically treated with NIRSCHL procedure for lateral release of the epicondyles and tangential resection of the epicondyle.
In the other patient, lateral release was performed, i.e., the collateral ligament was reconstructed with the transposition of the local extensor fascia septum.

RESULTS:

After the injection cycle, all patients reported a reduction in pain (assessed with VAS scale from 9 to 0), recovery of function and return to work and sporting activities.
Follow-ups were carried out at 1, 3, and 6 months by clinical evaluation and ultrasound.
There was strong evidence ($p<0.001$) of a statistically significant main effect across multiple clinical observations. Ultrasound showed an improvement in the structural integrity of the tendon. The MD TISSUE collagen injected into the intratendinous site acted on the degeneration of the tendon fibres, stimulating the synthesis of new collagen, restoring tendon structure and avoiding the need for surgery in most of the treated patients.

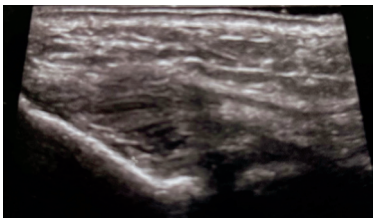

"Right elbow ultrasound of a patient suffering from lateral epicondylitis."

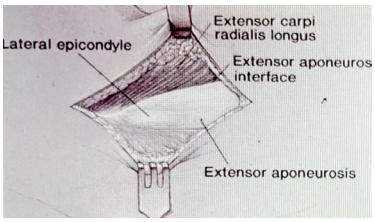

"Lateral elbow: extensor origin."

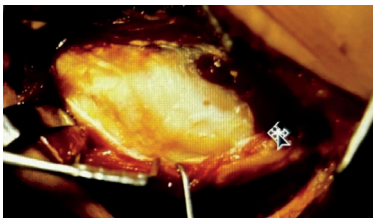

"Surgical treatment typically involves excision of the area of tendinitis, debridement of the local tissue bed, and reattachment of the tendon origin as indicated."

CONCLUSIONS:

Injections of Guna collagen MD Tissue have proven to be a safe and effective therapy compared to other injection therapies with corticosteroids, for instance, which act only on acute pain with the risk of damage to the tendon structures, and a cost-effective reparative and regenerative therapy, which is quick to use compared to PRP.
Collagen is among the novel regenerative therapeutic solutions.
It acts as an ECM scaffold on connective tissues that have suffered damage or wear, stimulates the synthesis of new collagen, repairs/regenerates tissues leading to functional healing, and allows a quicker return to sports activity.
Guna collagen allows to act on the reparative and regenerative phase, with a biological response that made it possible to speed up return to the sportive activity.

REFERENCES:

1. Randelli F, Menon A, Giai Via A, Mazzoleni MG, Sciancalepore F, Brioschi M, Gagliano N Effect of a Collagen-Based Compound on Morpho-Functional Properties of Cultured Human Tenocytes Cells. 2018 Dec 6;7(12):246
2. Karabinov V, Georgiev GP. Lateral epicondylitis: New trends and challenges in treatment. WJO 2022 Apr 18;13(4):354-364
3. Corrado B., Mazzuoccolo G., Liguori L., Chirico V.A., Costanzo M., Bonini I., Bove G., Curci L. Treatment of Lateral Epicondylitis with Collagen Injections: a Pilot Study MLT Journal 2019 9(4):584-589

FINGERS - HAND

ISOKINETIC MEDICAL CONFERENCE · ATHENS 2026

Collagen Injections for Hand and Wrist Tendon and Ligament Injuries in Elite Athletes

De Vitis R.[1] Guzzini M.[2] Rocchi L.[3] Passiatore M.[4] Lombardi L.[5]

[1] Fondazione Policlinico A. Gemelli IRCCS, Roma · [2] UniCamillus — International Medical University, Roma · [3] Università Cattolica del Sacro Cuore, Roma

[4] "Spedali Civili" Hospital, University of Brescia · [5] Fisioterm, Roma e Ferentino (FR)

INTRODUCTION & PURPOSE

Level of Evidence: IV — Prospective Case Series

Hand and wrist **tendon and ligament pathologies** represent a significant clinical challenge in elite athletes, particularly in sports requiring repetitive gripping and high-impact motions.

Sports most affected: Boxing · Paddle · Tennis — high-intensity, repetitive wrist/hand loading

CLINICAL PROBLEM

- Prolonged recovery periods with conventional treatment
- Potential career interruption
- NSAIDs, physiotherapy and rest often provide **suboptimal outcomes** in high-performance athletes
- Strong demand for **rapid return to competition**

RATIONALE FOR COLLAGEN

Porcine collagen-based devices act as a **biological scaffold**, promoting tissue regeneration and providing mechanical structural support — offering a minimally invasive bridge to surgical intervention.

Key Reference: Randelli PS et al. demonstrated MD-Tissue collagen acts as a mechanical scaffold influencing morpho-functional tissue properties. *Cells* 2020;9(12):2641.

STUDY OBJECTIVE

Evaluate the clinical efficacy of **porcine collagen injections** in hand/wrist tendon and ligament pathologies in elite athletes, assessing *pain reduction* and *functional recovery* over a 12-week follow-up.

MATERIALS & METHODS

STUDY DESIGN

Prospective case series — **10 elite athletes** with chronic hand/wrist tendon or ligament pathologies unresponsive to conservative treatment.

3	4	3
Boxers	Paddle	Tennis

INCLUSION CRITERIA

- Tendon/ligament injury confirmed by **ultrasound imaging**
- Conservative treatment failure ≥ **6 weeks**
- Active competition status at time of enrolment

EXCLUSION CRITERIA

- Inflammatory systemic conditions
- Allergy to porcine-derived products

TREATMENT PROTOCOL

Porcine collagen-based medical device — perilisional and intralesional injections administered at the site of tendinopathy or ligament injury under imaging guidance.

Dosing: Mean 2 injections per patient · 1-week interval between injections

OUTCOME MEASURES

- **VAS** — Visual Analog Scale (0–10): Baseline, 4 wk, 8 wk, 12 wk
- **DASH** — Disabilities of the Arm, Shoulder and Hand score
- **MHQ** — Michigan Hand Questionnaire (multi-domain)
- **ROM** — Goniometry: wrist flexion/extension, digital joints
- **Grip Strength** — Hydraulic dynamometer (bilateral comparison)

Total follow-up: 12 weeks post-initial injection

RESULTS

75%	68%	72%	9/10
Pain Reduction	ROM Gain	Grip Strength Increase	RTS ≤ 2 weeks

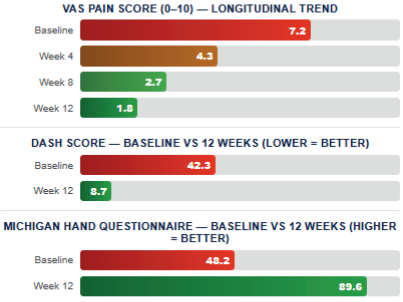

No adverse reactions or complications recorded during treatment period or 12-week follow-up.
One paddle player required additional injection cycle — full RTS achieved at week 8.

CASE EXAMPLE 2 — MP COLLATERAL LIGAMENT — ELITE OLYMPIC BOXER (SORRENTINO GIORDANA)

Patient: Sorrentino Giordana | **Sport:** Boxing — Italian Olympic National Team (EA7) | **Diagnosis:** MCP collateral ligament tear — ultrasound confirmed (25/04/2023)



FINDINGS & PROCEDURE

- US: MCP collateral ligament thickening (Ø 3.26–3.29 mm), hypoechoic signal, structural fibre disorganisation
- Clinical instability on lateral stress testing of the MCP joint
- Peri- & intralesional porcine collagen injection under US guidance
- Structured physiotherapy and taping protocol during return-to-boxing phase
- Progressive load reintroduction — bag work, sparring, competition

Successfully qualified for Paris 2024 Olympics
Italian National Boxing Team · EA7 Emporio Armani · Full competition training achieved within Olympic preparation timeline

CASE EXAMPLE 1 — ECU TENDINOPATHY — JUNIOR ELITE TENNIS PLAYER (FAUSTINI)

Patient: Faustini | **Sport:** Tennis — Junior Elite | **Diagnosis:** Extensor Carpi Ulnaris (ECU) tendinopathy — confirmed MRI & US



FINDINGS & PROCEDURE

- MRI: ECU tendon structural disorganisation, peritendinous oedema, partial-thickness tear
- Conservative treatment failure after 6 weeks (rest, NSAIDs, physiotherapy)
- Peri- & intralesional porcine collagen injection at ECU sheath level
- Adjuvant bilateral DreamK kinesio taping for proprioceptive support
- Protective wrist strapping during training re-integration phase

Outcome: Full return to junior elite tennis competition · VAS 7.0 → 1.5 at 12 weeks · Grip strength ↑ 70%



CONCLUSIONS

- Collagen-based injections demonstrate **excellent efficacy** as minimally invasive treatment for hand/wrist tendon and ligament pathologies in elite athletes
- **Pain** ↓ **75%** (VAS: 7.2 → 1.8) at 12-week follow-up
- **ROM** ↑ **68%** across all measured joints; greatest gains in wrist flexion-extension
- **Grip strength** ↑ **72%**, approaching contralateral limb values
- **DASH** 42.3 → 8.7 · **MHQ** 48.2 → 89.6 at 12 weeks
- **9/10 athletes** returned to full competition within 2 weeks
- **Zero adverse events** or complications recorded

Collagen injections represent a safe, effective and expedited therapeutic alternative to prolonged conservative management or surgical intervention in high-performance athletes requiring rapid return to competition.

Limitation: Small case series (n=10), no control group — Level IV evidence. Prospective randomised controlled trials are warranted to confirm these preliminary findings.

ISOKINETIC MEDICAL GROUP
FIFA MEDICAL CENTRE OF EXCELLENCE
XXXIII ISOKINETIC CONFERENCE
FOOTBALL MEDICINE
RETURN TO PERFORMANCE
18th, 19th, 20th, April 2026 • Athens, Greece



BIO THERAPIES IN EXTENSOR CARPI ULNARIS TENDONITIS: CASE SERIES IN RUGBY PLAYERS

Stefano Tognon, *Casa di Cura MediClinic - Pozzonovo (PD)*
Ilaria Fantoni, *Ospedale Santorso - Vicenza*
Alberto Inglese, *Ospedale Schiavonia - Monselice (PD)*
Stefano Turchetta, *Casa di Cura MediClinic - Pozzonovo (PD)*
Marco Necchi , *Clinica s. Martino - Lecco*

INTRODUCTION AND PURPOSE:

Extensor carpi ulnaris (ECU) tendonitis is one of the most frequently observed wrist tendinopathies in sports involving repeated loading during pronation/supination, ulnar deviation, and direct impacts, such as rugby, tennis, and combat sports.

This condition causes pain on the ulnar side of the wrist, worsened by functional loading and forced supination/ulnar deviation of the wrist (the so-called "dart-throw motion"), and may significantly limit performance and delay return to competitions.

The management of wrist tendinopathies includes conservative treatments such as rest, load control, physiotherapy, manual therapy, but, in selected cases, infiltrative or surgical treatments.

The aim of this case series was to evaluate the efficacy and safety of ultrasound-guided porcine collagen injections in a cohort of three high-level rugby players with ECU tendonitis, assessing pain, function, ultrasonographic assessments and return to sport at 3 months.

METHODS:

Three high-level rugby players (two females and one male), aged 19, 22, and 25 years, with chronic ulnar-sided wrist pain lasting at least 8 weeks (range 7–16 weeks), were treated. ECU tendinopathy was clinically and ultrasonographically confirmed in all cases (dominant side in all athletes).

All athletes presented spontaneous local pain exacerbated by maximal supination and ulnar deviation against resistance, reduced grip strength, and functional limitation during sports activity.

The protocol consisted of three ultrasound-guided infiltrations with porcine collagen (2 ml MD-TISSUE), performed at 7-day intervals using a 30G, 13-mm needle, in the peri-tendinous region of the ECU, under aseptic conditions and after local anesthesia with 2% lidocaine. During the first week, a rigid wrist brace was applied.

All athletes continued physiotherapy with eccentric strengthening exercises and load modulation. Pre-treatment and follow-up evaluations at 15, 30, and 90 days included pain scale (NRS), wrist-specific functional scores, QuickDASH, time to return to sport, and ultrasound examination.



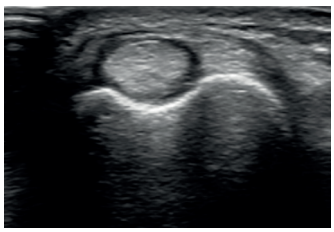

Ultrasound (US) revealed an inflamed tendon with peritendinous effusion

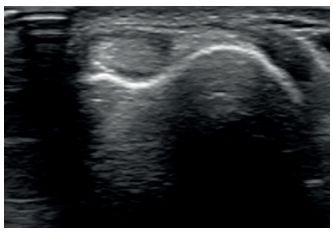

Ultrasound (US) showed resolution of tendon inflammation after treatment with MD-Tissue collagen

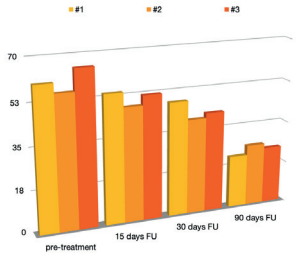

QuickDASH

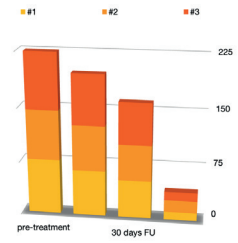

PRWHE



Synergy-test



Heart-test

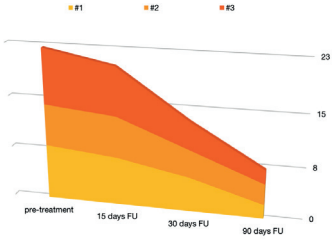

NRS

RESULTS:

All patients reported a significant reduction in pain (NRS) at the 3-month follow-up. An improvement in wrist-specific functional scores and a return to full-load rugby activity between 8 and 10 weeks were observed.

Ultrasound examination at the end of treatment showed a reduction in tendon hypoechogenicity and improved homogeneity of tendon fibers, indicative of possible new collagen synthesis and tissue remodeling induced by porcine collagen.

No adverse events were observed; the doping-free certification of porcine collagen represents an additional safety factor and risk reduction.

CONCLUSIONS:

In this preliminary case series of three professional rugby players with extensor carpi ulnaris tendonitis, treatment with ultrasound-guided porcine collagen injections, combined with targeted physiotherapy, showed promising results in terms of pain reduction, functional improvement, and rapid return to sport, due to the regenerative and reparative effects of porcine collagen on tendon tissue.

Larger sample sizes are required to confirm clinical efficacy and to define optimal protocols for the treatment of wrist tendinopathies in athletes.

REFERENCES:

1. Zarro M, Goel R, Bickhart N, et al. Extensor carpi ulnaris tendinopathy in athletes: a review of conservative and rehabilitative options. Hand (N Y). 2022; PubMed PMID: 36250572.
2. Frizziero A, Maffulli N, Saglietti C, et al. A practical guide to injection therapy in hand tendinopathies: systematic review of RCTs. J Funct Morphol Kinesiol. 2024.
3. Randelli et al. The Collagen-Based Medical Device MD-Tissue Acts as a Mechanical Scaffold Influencing Morpho-Functional Properties Cells 2020 Dec ;9(12): 2641.

SICM
Società Italiana di Chirurgia della Mano
63° CONGRESSO NAZIONALE
SOCIETÀ ITALIANA CHIRURGIA DELLA MANO
2-4 OTTOBRE 2025 - MILANO

COLLAGEN INJECTION THERAPY OF STENOSING TENOSYNOVITIS OF THE FLEXOR TENDONS OF THE FINGERS ("TRIGGER FINGER"): *CASE SERIES*

DEL GIUDICE MARINELLA
General Practitioner, Medico di Medicina Generale, Umberto I Polyclinic University Hospital, Rome

DI CESARE ANNALISA
Director, UOC of Physical and Rehabilitation Medicine, Umberto I Polyclinic University Hospital, Rome

INTRODUCTION

Stenosing tenosynovitis of the flexor tendons of the fingers ("trigger finger") is a common hand disease that, depending on its stage and severity, can cause pain and severe functional limitation.
Collagen injections may represent an effective therapeutic solution and a safe alternative to conservative therapies (cortisone, hyaluronic acid, PRP), physical-instrumental, or surgical treatments. The collagen-based infiltrative medical device acts as a "bio-scaffold" of the extracellular matrix with a reparative and regenerative effect, affecting tissue remodeling, preventing the formation of fibrotic tissue, and modulating the inflammatory state, leading to functional healing.
The aim of the study is to demonstrate the efficacy of in the injections treatment with MD-Tissue (Guna S.p.A., Milan, Italy) in the treatment of trigger finger, using response times as an outcome, in relation to the different pathophysiological stages.

MATERIALS AND METHODS

On 14 patients with trigger finger (Quinnell Scale Grade 2-3), never previously treated, a cycle of 5 peritendinous infiltrations with 2 ml of MD-Tissue was performed, once a week for 5 weeks.
Pain, general performance status, and function were assessed using the NRS, Karnofsky PSS, and Quick DASH rating scales at T0 (pre-treatment), T1 (after the first infiltration), T3 (after the third), T5 (after the fifth), and T6 (after 6 months).

RESULTS

All patients completed the treatment, without side effects or allergic reactions.
NRS: Initial mean value: 7.4, with a reduction at T1 of 6.2, T3 of 4.4, T5 of 1.4, T6 of 0.9.
KARNOFSKY: Initial mean value: 69.3%, with an increase at T1 of +3.6%, T3 of +15.0%, T5 of +23.6%, T6 of +28%.
QUICK DASH: Initial mean value of 43.5%, with a reduction at T1 of -3.9%, T3 -17.5%, T5 of -35.7%; T6 of -39.6%.
In all scales, the improvement initially appears limited (T0/T3), then becomes significant at T5 and especially at T6.

CONCLUSIONS

This study demonstrates that injection therapy with Guna's MD-Tissue collagen medical device is an effective option for the treatment of trigger finger, with a clinical response curve that reflects the phases of inflammation and connective tissue restoration, showing significant improvements in pain and function, with a high safety profile and a favorable cost-benefit ratio compared to other conventional therapies. However, further studies are needed, on larger sample sizes, over a longer period of time, and also in combination with other adjuvants.

TRIGGER FINGER

Stenosing tenosynovitis where a finger gets stuck in a bent position and then snaps straight.

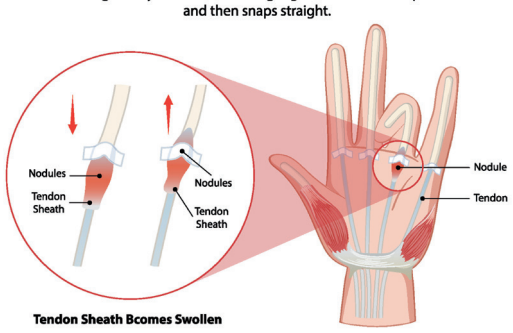

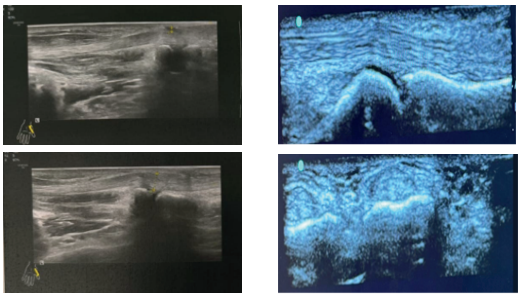

PRE-TREATMENT QUINNELL SCALE 3

6 MONTHS POST TREATMENT QUINNELL SCALE 0

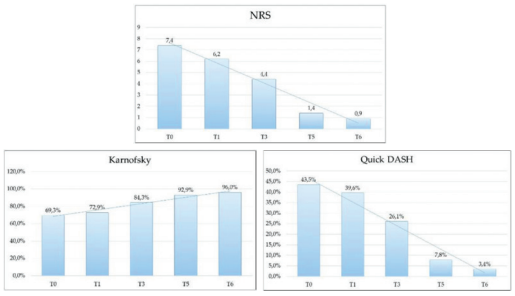

CHART OF AVERAGE VALUES ON THE FUNCTIONAL ASSESSMENT SCALES

BIBLIOGRAPHY:

1. Mezian K. et al. Ultrasound Imaging and Guidance in Common Wrist/Hand Pathologies. Am J Phys Med Rehabil. 2021 Jun;100(6):599–609
2. Randelli F.et al. The Collagen-Based Medical Device MD-Tissue Acts as a Mechanical Scaffold Influencing Morpho-Functional Properties of Cultured Human Tenocytes. Cells. 2020 Dec 8;9(12):2641
3. Wen J et al. Percutaneous A1 pulley with corticosteroid injection for trigger finger release: a systematic review. J Orthop Surg Res. 2025 Apr 29;20(1):431.

SIMFER
SOCIETÀ ITALIANA DI MEDICINA FISICA E RIABILITATIVA
The Italian Society of Physical and Rehabilitation Medicine

UPO UNIVERSITÀ DEL PIEMONTE ORIENTALE

POSTER N. 146

53° CONGRESSO NAZIONALE SIMFER
RICERCA E INNOVAZIONE IN MEDICINA FISICA E RIABILITATIVA
NAPOLI
23 | 26 NOVEMBRE 2025



TREATMENT OF POST-SURGERY HAND ADHESION SYNDROME WITH COLLAGEN: TWO CASE REPORTS

Enrico Cavallo[1], **Arianna Folli**[2], **Anna Scavia**[2], **Monica Fulvia Barberis**[2], **Maria Luisa Niola**[1], **Marco Invernizzi**[1, 3]

[1] Università del Piemonte Orientale "A.Avogadro", Physical Rehabilitation Medicine, Department of Health Sciences, Alessandria
[2] University Hospital SS. Antonio e Biagio e Cesare Arrigo, Physical Rehabilitation Department, Alessandria
[3] University Hospital SS. Antonio e Biagio e Cesare Arrigo, Division of Translational Medicine, Department of Integrated Activities, Research and Innovation, Alessandria

AOU AL Azienda Ospedaliero Universitaria di ALESSANDRIA Santi Antonio e Biagio e Cesare Arrigo

INTRODUCTION

Adhesions are a frequent complication of hand disorders, following trauma or surgery. This complication, in most cases, leads to a significant reduction in the function of the flexor tendons and the onset of pain, often preventing the return to manual and work activities.
Adhesions result from a scarring process involving the deposition of type III collagen, with disorganized fibers that compromise the sliding between the tendon and synovial sheath during finger flexion and extension.
The standard treatment for symptomatic adhesions of the flexor tendon is tenolysis and early mobilization. In recent years, several absorbable polymer-based products have been developed. These products act as physical barriers to prevent the formation of adhesions and are used as a tendon wrap or covering after tenolysis and tendon repair. Conservative treatments for symptomatic adhesions include the use of hyaluronic acid-based gels, formulated with a self-crosslinking technology that allows them to adhere to the tendon surface, preventing contact with surrounding tissue in the early stages of post-surgical healing.
Another valid therapeutic option is porcine collagen, which, acting as a "bio-scaffold" of the extracellular matrix with repair and regenerative actions, facilitates tissue remodeling, preventing the formation of fibrotic tissue. It is already used to treat tendon disorders with good results in terms of pain reduction and functional improvement. Positive experiences have also been reported during and after shoulder and hand surgery; however, there are currently no studies evaluating its application in the management of post-surgical hand adhesion syndrome. Adequate rehabilitation after flexor tendon repair reduces pain and restores function, but it cannot prevent the formation of adhesions or their recurrence after tenolysis.

MATERIALS AND METHODS

Two female patients (A and B), both post-tenoplasty of the superficial flexor tendon of the hand (FSD), treated at the Physical Medicine and Rehabilitation Outpatient Clinic of the "Teresio Borsalino" facility of the SS. Antonio e Biagio and Cesare Arrigo University Hospital of Alessandria, with post-surgical adhesion syndrome, symptomatic of pain and functional limitation, underwent a cycle of ultrasound-guided weekly injections along the adhesion tension with porcine collagen (2 ml of Guna MD TISSUE) and 0.5 ml of lidocaine, with the aim of mechanically removing the adhesions. Along with the injection treatment, the patients underwent 20 sessions of motor re-education and manual treatment of the scars.
The primary outcomes, assessed at pre-treatment T0, post-treatment T1, and at T2 through a two-month follow-up, were the reduction of pain symptoms using the Numeric Rating Scale (NRS) and the recovery of function, assessing joint grade.

COLLAGEN

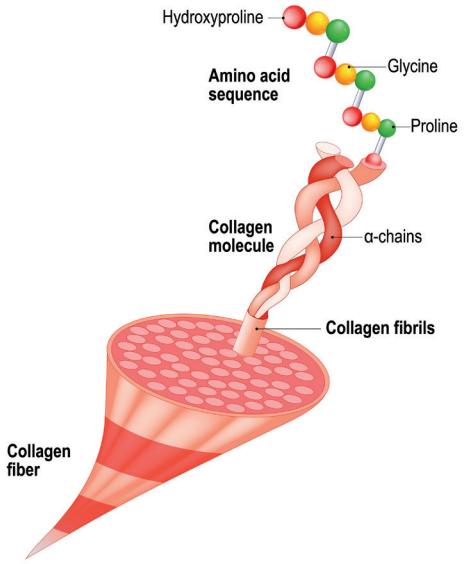

	Sesso, età	*Tendine coinvolto*	*N infiltrazioni*	*T0 NRS*	*T1 NRS*	*T2 NRS*
Paziente A	F, 43 anni	FSD II raggio	3	10	7	7
Paziente B	F, 51 anni	FSD V raggio	4	6	3	3

Abbreviazioni: F: femmina, FSD: flessore superficiale delle dita, N: numero, NRS: numeric rating scale, T0: pre-trattamento, T1: post-trattamento, T2: follow up.

RESULTS

Patient A (43 years old, post-secondary ray FSD tenoplasty) underwent three injections, presenting an NRS of 10 at T0 and an NRS of 7 at T1. The functional limitation persisted, and the patient was referred to another center for orthopedic reevaluation.
Patient B (51 years old, post-secondary ray FSD tenoplasty) underwent four injections, presenting an NRS of 6 at T0 and an NRS of 3 at T1 post-treatment. At the fourth session, in combination with collagen, the lidocaine dosage was increased to 2 ml. Patient B remained with a mild functional limitation that did not affect the performance of the most common daily activities.
The reduction in pain symptoms was shown to be sustained over time: at two months (T2), the patients were interviewed by telephone and confirmed the reduction in pain, with no reports of adverse events.

CONCLUSIONS

The use of porcine collagen has proven safe and effective in managing pain symptoms from post-surgical hand adhesions. Its bioscaffold action allows it to adhere to connective tissues, facilitating their remodeling and reducing the formation of fibrotic scar tissue responsible for adhesions. The mechanical action of MD TISSUE collagen infiltrated into the tendons of the hand facilitates joint range of motion, improving their functionality and also enhancing the effect of associated physiotherapy. Although the results are preliminary and limited to two cases, the combined approach with physiotherapy treatment suggests potential clinical utility.
Further studies with a larger sample size are needed to strengthen these findings.

BIBLIOGRAPHY:

1. Titan AL et al Flexor Tendon: Development, Healing, Adhesion Formation, and Contributing Growth Factors. Plast Reconstr Surg. 2019 Oct;144(4):639e-647e.
2. Vinitpairot C. et al Current trends in the prevention of adhesions after zone 2 flexor tendon repair. J Orthop Res. 2024 Oct;42(10):2149-2158.
3. Randelli F. et al The Collagen-Based Medical Device MD-Tissue Acts as a Mechanical Scaffold Influencing Morpho-Functional Properties of Cultured Human Tenocytes. Cells. 2020 Dec 8;9(12):2641.

SIMFER
SOCIETÀ ITALIANA DI MEDICINA FISICA E RIABILITATIVA
The Italian Society of Physical and Rehabilitation Medicine

POSTER N. 195

53° CONGRESSO NAZIONALE SIMFER
RICERCA E INNOVAZIONE IN MEDICINA FISICA E RIABILITATIVA
NAPOLI
23 | 26 NOVEMBRE 2025



INFILTRATIVE THERAPY FOR STENOSING TENOSYNOVITIS OF THE FLEXOR TENDONS OF THE FINGERS ("TRIGGER FINGER"): TREATMENT OF 22 CASES WITH MD TISSUE COLLAGEN MEDICAL DEVICE

Del Giudice Marinella Umberto I Polyclinic University Hospital, Rome
Di Cesare Annalisa Umberto I Polyclinic University Hospital, Rome

INTRODUCTION

Trigger finger (stenosing tenosynovitis of the flexor tendons of the fingers) is a common hand disease that, depending on its stage and severity, can cause intense pain and severe functional limitation.
As an alternative to conservative therapies with short-term pharmacological therapies (oral NSAIDs or infiltrative corticosteroids) or physical therapies (laser, ultrasound) or surgical therapies (puleggiotomy), local infiltration with collagen can represent an effective and safe therapeutic solution. The collagen medical device acts as a "bio-scaffold," both by providing mechanical support and by inducing autologous repair and remodeling mechanisms of the connective tissue, starting from the capacity of fibroblasts, promoting the physiological evolution of inflammation. Collagen injections may be beneficial for both repair and regeneration, reducing pain and improving function. The purpose of this case series is, therefore, to demonstrate the effectiveness of infiltrative treatment for trigger finger, especially focusing on the response times in relation to the different pathophysiological stages.

MATERIALS AND METHODS

In this case series we treated 22 patients with a clinical diagnosis of Quinnell grade 2 or 3 trigger finger, who had never previously been treated with surgery or local infiltration therapies. All patients received a single peritendinous infiltration of MD Tissue collagen medical device (Guna S.p.A., Milan, Italy), one 2 ml vial per week for 5 consecutive weeks. All patients completed the entire treatment cycle, with the recommendation not to take other analgesic or anti-inflammatory medications, either locally or systemically. The progression of pain, function, and quality-of-life implications of the condition were evaluated over time, with progression occurring after the infiltrations were performed.
Specifically, at T0 (pre-treatment), T1 (after the first injection), T3 (after the third injection), T5 (after the fifth infiltration), T6 (six months after treatment), and T12 (one year after treatment), the following were administered: the NRS (Numerical Rating Scale); the Karnofsky Performance Status Scale; and the Quick DASH (Disability of the Arm, Shoulder, and Hand Scale).

RESULTS

All patients completed treatment. None reported any side effects or allergic reactions after product administration.
The following were evaluated:
NRS SCALE: The mean initial value was 7.5 ± 0.8; after the first injection (T1), the value dropped to 6.4 ± 1.1, after the third (T3), to 4.8 ± 1.2; at the end of treatment (T5), it reached 1.5 ± 1.1; after 6 months (T6), it was 1.2 ± 1.2; after one year (T12), it rose slightly to 1.5 ± 1.3.
KARNOFSKY INDEX: The mean initial value was 69 ± 7.1%, which increased over time, with a mean difference of: +4 ± 5.9% at T1; +14 ± 8.5% at T3; +24 ± 8.4% at T5; +25 ± 9.9% at T6; no differences (0%) were recorded between this last value and the annual check-up at T12.
QUICK DASH SCALE: This functional assessment scale, specifically focused on the upper limb, showed a mean initial value of 43.9 ± 5.3%. Over time, the perceived disability score decreased, with a mean difference of: -3.3 ± 1.9% at T1 compared to the initial value; -16.1 ± 4.8% at T3; -31.8 ± 16.4% at T5; -39.4 ± 3% at T6, with an absolute mean value of 4.5 ± 3.5%; Between the sixth month and the annual check-up at T12, a slight increase of 1.7 ± 2% was observed.
Across all assessment scales, an initially slow response was observed, with little perceived difference, especially in the first 3 weeks of treatment (T3), particularly with regard to functional aspects. In the long term (T6), however, an improvement was observed in all parameters and, above all, excellent maintenance even one year after the end of treatment (T12), with values even better than those immediately following the end of the infiltration cycle (T5), especially with regard to functional assessment scales.

CONCLUSIONS

This study shows that local infiltration therapy with MD Tissue (Guna S.p.A., Milan, Italy) collagen medical device is a potentially effective option for the treatment of trigger finger, with a clinical response curve that reflects the various phases of the inflammatory process and the restitution of connective tissue. The response to therapy appears initially slow and mild, but on the other hand, it remains excellent, especially in the long term. This therapy therefore appears very promising in this clinical setting, also considering its high safety profile, but further studies on larger, longer-term samples are needed to confirm its efficacy and therapeutic protocol.

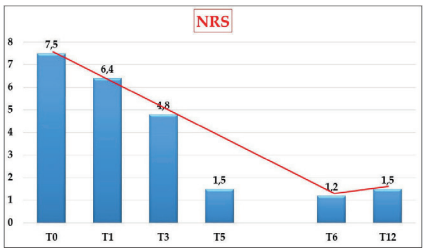

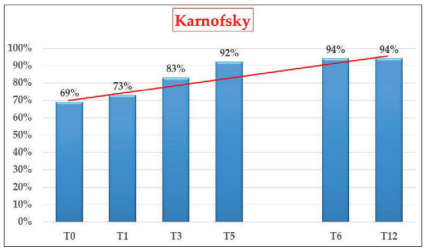

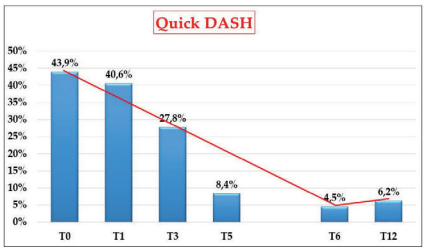

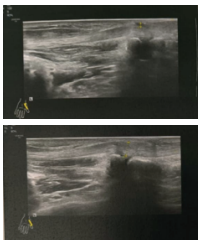

PRE-TREATMENT
QUINNELL SCALE 3

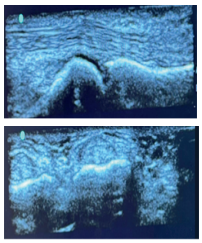

6 MONTHS POST TREATMENT
QUINNELL SCALE 0

BIBLIOGRAPHY:

1. Donati D, Ricci V, Boccolari P, Tedeschi R, Origlio F, Vita F, Nańka O, Catani F, Tarallo L. Trigger Finger: A Narrative Review of Dynamic Ultrasound and Personalized Therapies. J Clin Ultrasound. 2025 Mar 21. doi: 10.1002/jcu.23971. Epub ahead of print. PMID: 40119539.
2. Randelli F, Sartori P et al. The Collagen-Based Medical Device MD-Tissue Acts as a Mechanical Scaffold Influencing Morpho-Functional Properties of Cultured Human Tenocytes. Cells. 2020.
3. Zaolino CE et al. Le tendinopatie dell'arto superiore – Nuove soluzioni infiltrative con Collagen Medical Devices, La Med. Biol, 2023/4; 15-21.

3rd ANNUAL MEETING
SIAGASCOT
SOCIETÀ ITALIANA ARTROSCOPIA - GINOCCHIO - ARTO SUPERIORE
SPORT - CARTILAGINE - TECNOLOGIE ORTOPEDICHE
BARI
21-23 MARCH 2024
THE NICOLAUS HOTEL

RECURRENCE OF DE QUERVAIN IN MUSICIAN: COMBINED FOCUSED SHOCK WAVE TREATMENT AND INJECTION THERAPY USING INJECTABLE COLLAGEN

ALBERTO FORMIS
Physiatrist - Head of Unit San Clemente Mantova

Fondazione Teresa Camplani
S. CLEMENTE Nursing Home

AIM

Description of the clinical case of a musician - bass player suffering from relapsing De Quervain syndrome.

METHOD

Patient aged 30, right-handed, bass player, surgically treated in 2017. Following the failure of conservative physiotherapy for tenolysis on the abductor pollicis longus (APL) and extensor pollicis brevis (EPB), the patient underwent an MRI on the right wrist one year later. This showed normal representation of the triangular fibrocartilage with fibro-cicatricial results in the integuments along the course of the 1st compartment of the extensors in the region of the radial metaphysis resulting from previous surgery. The thickness and structure of the tendons of the APL and EPB muscles were within limits.

The patient came to our attention in January 2022 due to persistent, debilitating painful symptoms in the area of radial styloid and positive Finkelstein sign. He reported that the disorder occurred approximately 30 minutes after the start of activity, with persistent pain, albeit reduced, in the following hours despite rest.

In light of this condition, an indication was given for a cycle of focused shock waves (4) followed by a cycle (5) of peritendinous injection sessions using Guna collagen MD-Tissue (class III medical device) one month later. The patient underwent 4 focused shock wave sessions (ESWT) at weekly intervals - 2000 pulses per session - with an average energy flux density (EFD) of 0.10- 0.18 mmJ/mm2 - Frequency 6-8 Hz) using EMS equipment (piezoelectric generator) - all sessions were carried out by the same practitioner; the subject then underwent 5 injection sessions using Guna Collagen through an ultrasound-guided technique in the peritendinous region.

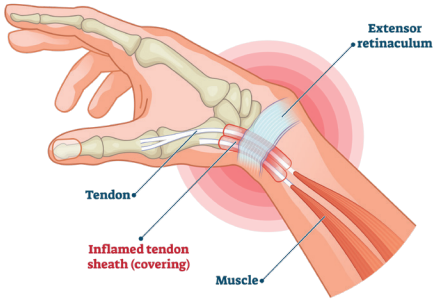

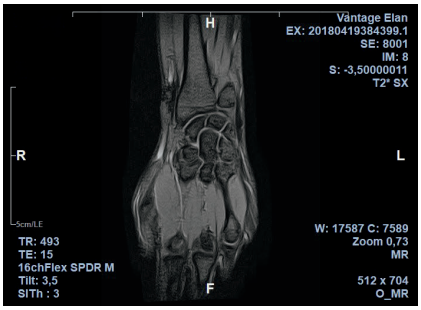

RIGHT WRIST MRI

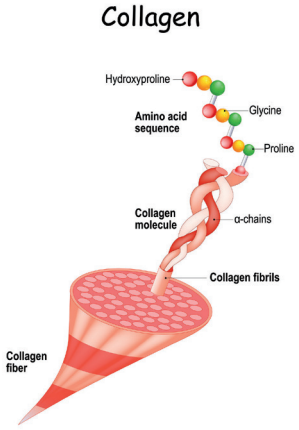

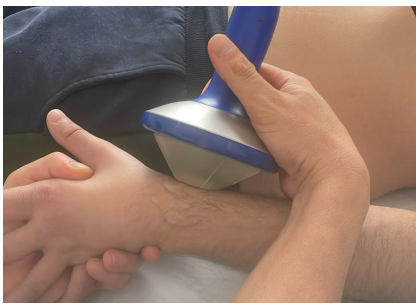

RESULTS

The ESWT treatment was well tolerated; during a check-up one month after completion of the ESWT, the patient reported a significant reduction in painful symptoms during use (NRS 8 > 5), while the pain when at rest had completely regressed. After the injection cycle the patient reported almost complete regression of the symptoms (NRS 2).

CONCLUSION

The proposed combined therapy of ESWT and Md-Tissue injection proved effective and safe in the treatment of persistent painful symptoms following surgery for De Quervain syndrome.

REFERENCES:

1. Randelli F, Sartori P, Carlomagno C, Bedoni M, Menon A, Vezzoli E, Sommariva M, Gagliano N. The Collagen-Based Medical Device MD-Tissue Acts as a Mechanical Scaffold Influencing Morpho-Functional Properties of Cultured Human Tenocytes. Cells. 2020 Dec 8;9(12):2641.
2. Godek P, Szczepanowska-Wolowiec B, Golicki D. Collagen and platelet-rich plasma in partial-thickness rotator cuff injuries. Friends or only indifferent neighbours? Randomised controlled trial. BMC Musculoskelet Disord. 2022 Dec 20;23(1):1109.

NO. ID

30

CASE SERIES: INJECTABLE TREATMENT WITH COLLAGEN IN PATIENTS WITH RHIZOARTHROSIS

DR. MIRISOLA GABRIELE, DR. MANGONE GIUSEPPE, DR. SCARSELLI MATTEO

Introduction

Rhizoarthrosis is arthrosis of the trapeziometacarpal joint, which is located at the base of the thumb and allows the first finger to bend.
It is one of the most common degenerative joint diseases affecting mainly post-menopausal women. It is caused by weakening of the palmar oblique trapeziometacarpal ligament, which can cause pain and difficulty when gripping objects and twisting.
Conservative therapies include the use of injectable corticosteroids, orthoses and anti-inflammatory drugs; if ineffective, surgery may be necessary (arthrodesis, arthroplasty, trapeziectomy).



Materials and methods

Collagen has been found as an application in the management of this pathology, delaying or avoiding the surgical approach.
Collagen is a protein that makes up the extracellular matrix (ECM) and confers stress and load resistance to the tissues where it is present. It has been shown to be effective in reducing pain and recovering functionality.
Physiologically, from the age of 40, there is an imbalance between the production and degradation of collagen.
Therapy with MD-SMALL JOINTS involves collagen injection into the affected area, which is effective in stimulating collagen synthesis and creating a bioactive scaffold that strengthens intra- and periarticular structures by reducing pain, increasing mobility and improving joint stability.
We recruited 4 patients with painful joints who were administered 5 ultrasound collagen injections for each joint on a weekly basis.
Pain, disability and joint stability were assessed at T1 (first injection) and T2 (one week after the last injection session).
No adverse effects or periprocedural complications were reported.

Results

The degree of arthrosis was assessed by means of the "Grinding test"; the "Crank test" was used while pain was assessed by means of the NRS scale; the degree of disability was assessed by means of the Quick-DASH questionnaire.
The results showed a 22% improvement in pain relief and 11.4% improvement in disability after treatment. In addition, the number of positive grinding crank tests decreased during the treatment period.

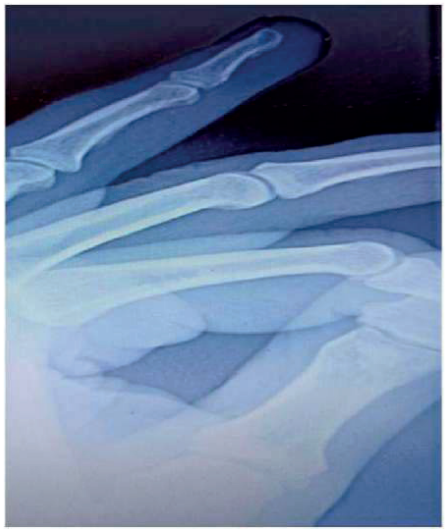

Conclusions

In summary, MD-SMALL JOINTS therapy based on collagen injection can be a treatment solution for rhizoarthrosis. This conservative approach can be useful for patients of all ages, pregnant women and patients with rare diseases, as the class III medical device poses no adverse risks to the patient and does not cause any cartilage or bone damage.
However, further studies are needed to assess the long-term effectiveness of this therapy.

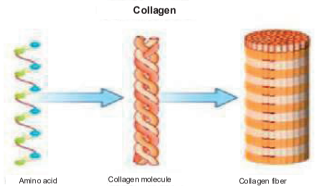

REFERENCES

1. Saltzman CL, Salamon ML, Blanchard GM, Huff T, Hayes A, Buckwalter JA, Amendola A. Epidemiology of ankle arthritis: report of a consecutive series of 639 patients from a tertiary orthopaedic center. Iowa Orthop J. 2005;25:44-6. PMID: 16089071; PMCID: PMC1888779.
2. Sangeorzan BJ, Ledoux WR, Shofer JB, Davitt J, Anderson JG, Bohay D, Coetzee JC, Maskill J, Brage M, Norvell DC. Comparing 4-Year Changes in Patient-Reported Outcomes Following Ankle Arthroplasty and Arthrodesis. J Bone Joint Surg Am. 2021 May 19;103(10):869-878. doi: 10.2106/JBJS.20.01357. PMID: 33983146.
3. Ricard-Blum S. The collagen family. Cold Spring Harb Perspect Biol. 2011 Jan 1:3(1):a004978.
4. Randelli F, Menon A, Giai Via A, et al, Effect of a Collagen-Based Compound on Morpho-Functional Properties of Cultured Human Tenocytes. Cells. 2018 Dec 6;7(12):246.
5. Randelli F, Sartori P, Carlomagno C, Bedoni M, Menon A, Vezzoli E, et al. The Collagen-Based Medical Device MD-Tissue Acts as a Mechanical Scaffold Influencing Morpho-Functional Properties of Cultured Human Tenocytes. Cells. 2020 Dec 8:9(12):2641.

51ST SIMFER NATIONAL CONGRESS
REHABILITATION OF THE PAST, PRESENT AND FUTURE.
WHO WE WERE, WHO WE ARE, AND WHO WE WOULD LIKE TO BE.
12-15 OCTOBER 2023

The use of collagen in the treatment of symptomatic rhizoarthrosis: preliminary results

F. Giarda[1], A. Parente[2], F. Cattaneo[2], F. Gervasoni[3], A. Robecchi[4], A. Caronni[4,5]

[1] Rehabilitation Medicine and Neurorehabilitation Department, ASST GOM Niguarda, Milan; [2]School of Specialisation Physical Medicine and Rehabilitation, University of Milan; [3]ASST Fatebenefratelli Sacco, Milan; [4]Department of Neurorehabilitation Sciences, San Luca Hospital, IRCCS Istituto Auxologico Italiano, Milan; [5]Department of Biomedical Sciences, University of Milan.

Introduction

Osteoarthrosis of the trapeziometacarpal (TM) joint, better known as rhizoarthrosis, is a condition that affects around 20% of the population over the age of 50. Symptoms are bilateral in 50% of cases. A considerable role in the pathogenesis is represented by TM instability, which may be secondary to ligamentous hyperlaxity or to repeated radial stress of the base of the I metacarpal bone, conditioning an increase of the luxating force and progressive relaxation of the capsular ligamentous apparatus. More specifically, a loosening of the intermetacarpal ligament, stretched between the base of the I and II metacarpal bones and limiting the abduction movement of the I finger, determines the progressive external subluxation of the base of the I metacarpal bone, resulting in the incongruence of the articular surfaces and the progression of the degenerative phenomena [1]. Clinically, patients present with localised pain at the base of the first toe, accentuated by active movements in radial abduction and/or passive movements in rotation-opposition, which may lead to a variable degree of strength deficit and functional limitation at rest and during activities, with a subsequent negative impact on quality of life [2]. **In vitro studies have proven the ability of collagen for injectable use to work within collagen turnover pathways, acting as a bio-scaffold with a reparative and regenerative action, while several in vivo works have shown improvements in terms of pain reduction and increased functionality following its intra- and peri-articular injectable use in the early stages of arthrosis located in different T3 joint districts. The aim of this study isto evaluate the possible efficacy and safety of using collagen-based medical devices in the treatment of symptomatic rhizoarthritis.**

Materials and methods

- ❑ Thirteen people [mean age 60.4 years; 11Fs, 2Ms] presenting a clinical picture of symptomatic rhizoarthrosis were enrolled, six of whom had bilateral symptoms.
- ❑ Patients did not undergo physical therapy or other local injectable treatments in the three months prior to recruitment. Each subject was given five intra-articular and peri-articular injections in the trapeziometacarpal joint, on a weekly basis, under ultrasound guidance with a 27G x 4mm needle.
- ❑ The VNS scale at rest (VNS-R) and during movement (VNS-A) was administered to quantify pain symptoms and the DASH questionnaire was used as an index of the functional impact of the pathology.
- ❑ All measurements were taken before starting the treatment (T0), during each injection session (T1-T4), at one month (T5) and at three months (T6) after the end of the treatment, to analyse the onset and duration of any improvements.

Results

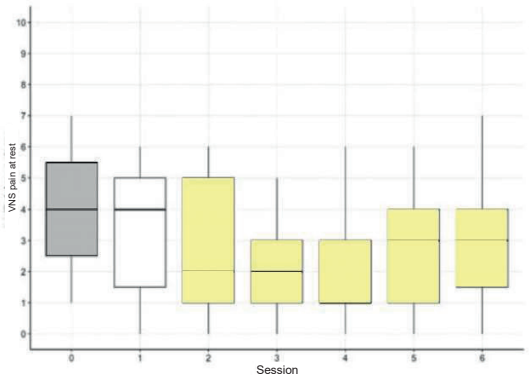

Figure 1

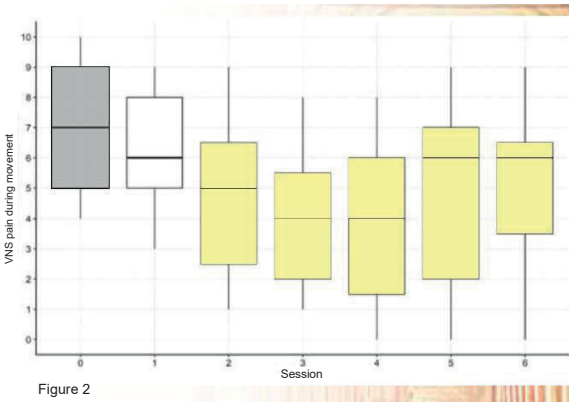

Figure 2

Graphical representation of pain trends during the observation period. Figure 1 shows the VNS values at rest and Figure 2 shows the VNS values during movement. Sessions that differ significantly from session 0 (in grey) are highlighted in yellow

- Our results showed a **statistically significant effect of the F0-F6 session ($F_{6,108}$ = 8,42; p < 0.001),** indicating that there are significant differences in the value of VNS-R in the different evaluation sessions, in particular:
The VNS-R score in the session **was significantly higher than in sessions 2 (p = 0.036), 3 (p < 0.001), 4 (p < 0.001), 5 (p < 0.001) and 6 (p = 0.022).**
- The VNS-A results substantially replicate the VNS-R ones, with a **statistically significant session effect.**
- DASH in session 0 is **significantly lower compared to the one collected in sessions 4 (p < 0.001), 5 (p < 0.0357) and 6(p < 0.0092).**

Conclusions

Injectable treatment using collagen medical devices may be **a viable alternative in the management of symptomatic rizoarthritis,** in view of its safety, ease of use and observed efficacy. However, further evidence is needed to better define the indications and limitations of the method.

References

1. Edmunds JO. Current concepts of the anatomy of the thumb trapeziometacarpal joint. J Hand Surg Am. 2011 Jan;36(1):170-82
2. Siviero P, Zambon S, Limongi F, Castell MV, Cooper C, Deeg DJ, Denkinger MD, Dennison EM, Edwards MH, Gesmundo A, Otero Á, Pedersen NL, Peter R, Queipo R, Timmermans EJ, van Schoor NM, Maggi S; EPOSA Research Group. How Hand Osteoarthritis, Comorbidity, and Pain Interact to Determine Functional Limitation in Older People: Observations From the European Project on OSteoArthritis Study. Arthritis Rheumatol. 2016 Nov;68(11):2662-2670
3. Brunato F. The treatment of rhizoarthrosis with collagen medical device small joints. Physiological Regulating Medicine, 2021; 3-12 Hao D, Wang J. Fixed-bearing vs mobile-bearing prostheses for total knee arthroplasty after approximately 10 years of follow-up: a meta-analysis. J Orthop Surg Res. 2021 Jul 6;16(1):437. doi: 10.1186/s13018-021-02560-w. PMID: 34229702; PMCID: PMC8259014.

POSTER NO.
56

SIMFER
SOCIETÀ ITALIANA DI MEDICINA FISICA E RIABILITATIVA
The Italian Society of Physical and Rehabilitation Medicine

COLLAGEN-BASED INJECTION THERAPY IN THE REHABILITATION PATHWAY OF BILATERAL RHIZOARTHROSIS.

Filippo Valgimigli[1]

1. Rehabilitation medicine and pain therapy - Studio Medico Valgimigli - Forlì

Introduction

Rhizoarthrosis is an arthritic condition that affects the joint at the base of the thumb, between the trapezius bone of the carpus and the first metacarpus, which allows the first finger of the hand to perform flexion, extension and bending movements to the other fingers.
It affects 20% of the adult population and accounts for about 10% of arthritic localisations; it is more frequent in women than in men (4:1 ratio).
In women, it frequently begins during the menopause, while in men it is more related to overuse. The causes may be repetitive stress on the joint and ligament laxity.
Treatment is initially conservative with the application of immobilisers and the simultaneous use of chondroprotectors. If this treatment is unsuccessful, injectable therapy with cortisone, hyaluronic acid and collagen can be used before proceeding to surgery.
The aim of the study is to evaluate the efficacy of peri-articular injections with GUNA MD-SMALL JOINTS collagen in a patient with bilateral rhizoarthrosis, in terms of pain reduction and improved mobility.

Materials and Methods

A 70-year-old female patient with a radiographic diagnosis of bilateral rhizoarthrosis was treated with five injections of MD-SMALL JOINTS once a week for three consecutive weeks, followed by a further two sessions at monthly intervals with two vials per session.
The peri-articular route of administration was performed at the base of the thumb bilaterally, using a 13mm 26G needle. No drugs and/or injectable medical devices were added, nor was physiotherapy or immobilisation with a brace carried out.
MD-SMALL JOINTS is a class III medical device based on collagen and viola odorata that has a mechanical bioscaffold effect, protects against wear and tear, reduces pain and improves the mobility of small joints.

Figure 1:*Hand Osteoarthrosis*



Figure 2:*Triple helix collagen*

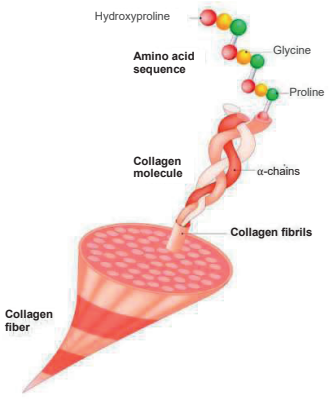

Results

A 50% reduction in inflammation, swelling and pain was reported by the patient after the first three injections, 80% after the fourth and 100% after the fifth according to the NRS (Numerical Rating Scale of pain). At the same time, joint mobility improved, enabling the patient to perform their normal daily movements.
Collagen used intra- and peri-articularly is effective in controlling pain symptoms, improving function and reducing joint instability.

Conclusions

After evaluating the decision to only perform this therapy and not to use the night brace, a very satisfactory result was found both in terms of the durability of the therapeutic effect and the patient's compliance. The doctor's high safety of use of the medical device should also be emphasised.

References

- Brunato F. La Med Biol 2021; 3: 3-12
- Randelli F, Menon A, Giai Via A, et al, Effect of a Collagen-Based Compound on Morpho-Functional Properties of Cultured Human Tenocytes. Cells. 2018 Dec 6;7(12):246.
- Randelli F, Sartori P, Carlomagno C, Bedoni M, Menon A, Vezzoli E, et al. The Collagen-Based Medical Device MD-Tissue Acts as a Mechanical Scaffold Influencing Morpho-Functional Properties of Cultured Human Tenocytes. Cells. 2020 Dec 8;9(12):2641.

Trigger finger ultrasound-guided injectable treatment with collagen. Initial clinical evidence.

Arianna Pesaresi[1], Vincenzo Ricci[2], Fabrizio Gervasoni[2], Federica Giarda[3], Antonio Robecchi Majnardi[4], Arnaldo Andreoli[2]

1. School of Specialisation in Physical and Rehabilitation Medicine, University of Milan, Milan,
2. Specialist Rehabilitation Unit, 'Luigi Sacco' Hospital, ASST Fatebenefrateili Sacco, Milan.
3. Rehabilitation Medicine and Neurorehabilitation Unit, ASST GOM Niguarda, Milan.
4. IRCCS Istituto Auxologico Italiano, Department of Neurorehabilitation Sciences, San Luca Hospital, Milan.

Introduction

Tenosynovitis of the finger flexor tendons, in most cases associated with the clinical condition described as 'trigger finger', is one of the most common causes of hand disabilities. It causes pain and difficulty in daily living and work activities, afflicting some *2%* of the world's population with a prevalence of up to 10% in diabetic patients. It mainly affects adult women in the dominant hand, particularly involving the third and fourth fingers. Flexor tenosynovitis occurs when the A1 pulley becomes thickened, preventing the tendons from moving freely during bending-extension movements. The difficulty in extending the affected finger when flexed is characteristic; the movement loses fluidity and a 'jerk' occurs, which is sometimes painful. The inflammatory state and hypervascularisation can be detected by an ultrasound, even on an outpatient basis. Treatment options may be conservative or surgical, depending on the severity of the condition. No standardised conservative protocols are currently available, although several injectable algorithms with therapeutic substances are reported in the literature. The aim of this in-depth methodological study is to illustrate the use of a class III medical device based on collagen *(e.g. MD-Tissue)* by injection in clinical pictures of trigger finger.

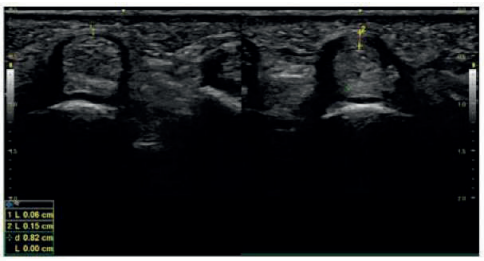

Figure 1:A short-axis ultrasound image of the A1 pulley in a physiological situation (left) and in a pathological situation (right) in which the fibrous thickening characteristic of trigger finger is visible and measurable.

Materials and Methods

After clinical and ultrasound diagnosis (Figure 1), written informed consent is collected from the patient to inform them of the risks of the method, as per hospital practice. The patient is placed lying down on the couch for protection in the event of any vaso-vagal reactions, with their hand in the supine position. After properly disinfecting the skin with *10%* iodopovidone solution *(e.g. Betadine)* the injection procedure is performed using a high-frequency probe for studying small joints (18 MHz) with sterile probe covers. We recommend the *in-plane technique,* with a probe and needle (22G gauge, length 32 mm) placed alongside one another to observe the needle and ensure it reaches the injection site properly [Figure 2]. The peri-tendon injection is given at the site of perceived 'snapping', targeting the tendon sheath. The uniform distribution of the device along the tendon is possible thanks to the procedure being shown via the ultrasound **(Figure 3).**

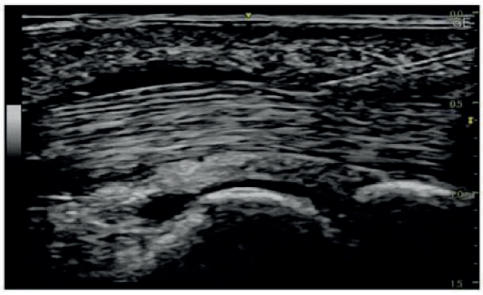

Figure 2:A long-axis ultrasound image obtained during an injection procedure. The needle tip in the INP ion technique is shown on the right and the injected medical device collection on the left.

Results

Following treatment, the treated patients (3) reported a progressive improvement in the perception of pain and stiffness in the affected finger (rating scales used: *Quinnell classification, NRS).* In view of the patients' clinical response, subsequent booster sessions were proposed with up to 3 injections in total.



Figure 3:A short-axis ultrasound image obtained following the peri-tendon injection procedure. A hypoechogenic halo surrounding the tendon component is displayed, indicating a correct and uniform distribution of the medical device.

Conclusions

The injectable treatment of trigger finger with collagen-based medical devices *(e.g. MD-Tissue)* is a safe medical practice, free of contraindications and easily performed with ultrasound guidance in an *outpatient setting.* Further studies will be needed to prove the efficacy of this treatment in hand flexor tenosynovitis by enrolling a larger cohort and setting up defined study protocols.



References

1. Shen PC, Chou SH, Lu CC. Comparative effectiveness of various treatment strategies for trigger finger by pairwise meta-analysis. Clin Rehabil. 2020 Sep;34(9):1217-1229. doi: 10.1177/0269215520932619. Epub 2020 Jun 15.

2. Bianchi S, Gitto S, Draghi F. Ultrasound features of trigger finger: review of the literature. J Ultrasound Med. 2019 Dec;38(12):3141-3154. doi: 10.1002/jum.15025. Epub 2019 May 20.

3. Randelli F, Sartori P, Carlomagno C. The collagen-based medical device MD-Tissue acts as a mechanical scaffold influencing morpho-functional properties of cultured human tenocytes. Cells. 2020 Dec 8;9(12):2641. doi: 10.3390/cells9122641.

HIP

8th International Symposium Intra Articular Treatment

Bucharest



INGUINAL DISRUPTION (ID) IN AN ELITE-LEVEL ATHLETE: non-surgical management with porcine collagen injections (MD-Tissue/MD-Muscle), ESWT, and targeted rehabilitation

G. RANDO, L. Ferraris, C. Foti

Physical and Rehabilitation Medicine, Department of Clinical Sciences and Translational Medicine, Tor Vergata University, 00133, Rome, Italy

ABSTRACT

Background: Inguinal disruption (ID) is a spectrum of groin injuries affecting the anterior pelvis in high-demand athletes. Non-surgical management aims to reduce pain, restore function, and enable return to play (RTP) while minimizing morbidity. This case report describes the non-surgical management of ID in an elite competitive American Football player using ultrasound-guided porcine type I collagen injections (MD Tissue/MD Muscle devices), combined with extracorporeal shockwave therapy (ESWT) and a structured rehabilitation program.
Case Presentation: A 22-year-old male elite student-athlete, formerly affiliated with NFL Academy and competing at a US University, developed right-sided adductor-related groin pain with acute exacerbation and localized tenderness near the rectus abdominis/pubis region. MRI revealed tears involving the rectus abdominis aponeurosis and later a tear at the common adductor/rectus abdominis aponeurosis with involvement of the conjoint tendon and pubic region. Initial conservative management (activity modification, one PRP injection, manual therapy, laser therapy, and multi-phased rehabilitation) partially alleviated symptoms but did not permit timely RTP. To avoid multiple PRP injections and accelerate safe RTP, a treatment strategy using four ultrasound-guided porcine collagen type I injections administered weekly was employed, with adjunct ESWT and a staged rehabilitation plan.
Intervention:
- Four ultrasound-guided injections of porcine collagen type I (MD Tissue/MD Muscle devices) targeted to the pre- and post-insertional regions of the adductor longus and the rectus abdominis aponeurosis, spaced one week apart.
- Adjunct focal ESWT sessions for pubic bone edema and associated osseous changes.
- A staged rehabilitation program implemented after the four injections, comprising three phases: Phase 1 (7 days) for pain control and controlled motion; Phase 2 (14 days) for stretching, strength, and stability; Phase 3 (21 days) for multi-planar strengthening, functional progression, and return to sport.
Outcomes:
- Post-treatment improvements included reduced groin pain during football-related activities, improved hip and groin mobility, and enhanced functional performance.
- Objective measures showed improved ROM, reduced palpation tenderness, and greater muscle elasticity in adductors, quadriceps, and hamstrings.
- Patient-reported outcomes demonstrated marked improvements in HAGOS subscales and LEFS scores.
- The athlete returned to the US to progressively resume training and competition, achieving 10 weeks post-injection RTP without limitations and reporting 85% of pre-injury performance at three months follow-up.
Discussion: This case supports the potential utility of porcine type I collagen injections as a regenerative, tissue-sparing option in ID, possibly providing a scaffold to promote remodeling in conjunction with biomechanical rehabilitation. The combination of collagen-based injections with ESWT and structured rehab may accelerate functional recovery and RTP. Mechanistically, injectable collagen acts as a biologically active scaffold to support extracellular matrix remodeling, facilitate collagen synthesis, and enhance tissue repair. Compared with PRP, collagen-based injections offer an alternative biomaterial approach aimed at structural restoration with favorable tolerability and potential cost benefits, and can be safely integrated with rehabilitation to accelerate return to play.
Clinical significance: The protocol leveraging MD-Muscle and MD-Tissue collagen devices, ESWT, and a staged rehabilitation program demonstrated promising results in accelerating RTP for ID in an elite American football athlete, with implications for broader adoption in high-demand sports while awaiting more robust prospective data
Conclusion: The collagen-based injectable strategy, when combined with ESWT and dedicated rehabilitation, may provide a viable, repair-oriented alternative to conventional biologic therapies for ID, supporting functional restoration and expedited RTP. Prospective controlled studies are warranted to compare collagen-based injections with biologics like PRP, optimize dosing schedules, and validate long-term outcomes across sports and levels of play

AIM

- Present a case report of ID in an elite university-level American Football athlete.
- Describe a multimodal non-surgical strategy integrating porcine collagen injections with ESWT and a structured rehabilitation program.
- Assess effects on pain, function, range of motion (ROM), muscle elasticity, and return to play (RTP)

BACKGROUND

- ID: spectrum of groin/epigastric injuries involving the anterior pelvis, potentially including the conjoint tendon, pubic region, and inguinal ligaments.
- Symptoms: groin/adductor pain, worsened with high-load sport movements, movement modifications, possible intra-articular hip pathology.
- Complications: limited RTP, potential long-term morbidity if not managed properly.
- Therapeutic goal: reduce pain, restore mobility and strength, progressively return to sport safely

CASE SUMMARY



- Patient: Italian 22-year-old male elite athlete, NFL Academy alumni, competing at a US university from NOV/2024 with right-sided adductor-related groin pain and acute exacerbation



Imaging: tear of the rectus abdominis aponeurosis; later, tear at the common adductor/rectus abdominis aponeurosis with conjoint tendon involvement, pubic oedema bone marrow



Feb/2025 Initial management in US

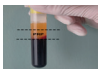

One PRP injection and laser therapy;
NSAIDs, activity modification



Multi-phased rehabilitation partial control of symptoms but inadequate RTP and stop playing







MAY/2025 Rationale for new protocol in Italy : to avoid multiple PRP injections and accelerate safe RTP

Intervention: 4 ultrasound-guided porcine collagen type I injections (MD Tissue/MD Muscle) weekly, with adjunct ESWT and staged rehabilitation.





Additional treatments: 3 weekly session with focal ESWT for pubic oedema and osseous changes



Rehabilitation program in three post-injection phases.
Outcome: pain reduction, improved ROM and elasticity; enhanced performance, HAGOS and LEFS assessment, RTP at 10 weeks post-injection without limitations; at three months, approximately 85% of pre-injury performance

INTERVENTION DETAILS - INJECTIONS:
-MD-Tissue: porcine type I collagen into the pre- and post-insertional regions of the right adductor longus tendon and rectus abdominis aponeurosis
-MD-Muscle: improved muscle mobility and reduced pain
-Frequency: 4 weekly injections

REHABILITATION: three-phase post-injection program:
Phase 1 (7 days): pain management and contolled motion.
Phase 2 (14 days): stretching, strength, stability, dynamic warm routine



Phase 3 (21 days): multi-planar strengthening, functional progression, RTP:



return to training | return to sport | return to play

INTERVENTION DETAILS - INJECTIONS:
AUG/2025 Main Outcomes
- Clinical: reduced groin pain during football activities; improved ROM; reduced focal tenderness; increased
elasticity of adductors, quadriceps, and hamstrings
- Functional: significant improvements in HAGOS subscales and LEFS
- RTP: returned to training and competition at 10 weeks post-injection; at 3 months,
~85% of pre-injury performance
- Safety: well-tolerated protocol; no major adverse events reported

DISCUSSION AND CLINICAL SIGNIFICANCE
- Preliminary evidence supports porcine type I collagen injections (MD-Tissue/MD-Muscle) as a regenerative
option for ID in high-level athletes, either as an alternative or complement to PRP
- Integration of collagen injections with ESWT and structured rehabilitation may accelerate functional recovery and RTP while preserving tissues and avoiding surgery
- Mechanism: collagen acts as a biologically active scaffold to support ECM remodeling and tissue regeneration; ESWT modulates edema and pain and may enhance local neurovascularization.
- Advantages: minimally invasive approach easily integrated with physical therapy; potential for shorter recovery time and cost advantages compared with other biologics
Limitations
Single-case design; need for prospective, controlled studies to compare collagen-based injections with PRP, optimize dosing and rehabilitation protocols across sports and levels of play

HOME MESSAGE
- An integrated protocol using MD-Tissue/MD-Muscle collagen injections, ESWT, and targeted rehabilitation
yielded rapid pain reduction, functional improvement, and RTP in an elite ID case
- Porcine collagen injections represent a viable reparative option that can be safely combined with rehabilitation to support return to play.
- Further prospective, multicenter studies are needed to compare collagen-based injections with biologics like PRP and to define optimal dosing, timing, and sport-specific rehabilitation strategies.
Practical Implications
- Consider collagen-based injections as part of a non-surgical strategy for ID in high-level athletes, in combination with ESWT and structured rehabilitation.
- Explore potential for reduced RTP timelines without compromising long-term safety, with sport- and role-specific rehabilitation

References
1. Manchester Consensus / British Hernia Society 2014 guidelines –
2. Serner A, van Eijck CH, Beumer BR, Holmich P, Weir A, de Vos R-J. Study quality on groin injury management remains low: a systematic review on treatment of groin pain in athletes. Br J Sports Med. 2015;50:1–11.
3. Yuill EA, Pajaczkowski JA, Howitt SD. Conservative care of sports hernias within soccer players: a case series. J Bodyw Mov Ther. 2012;16(4):540–548. doi: 10.1016/
4. Campanelli G. Pubic inguinal pain syndrome: the so-called sports hernia. Hernia. 2010;14(1):1–4.
5. Sheen AJ, Stephenson BM, Lloyd DM, et al. "Treatment of the Sportsman's groin". British Hernia Society's 2014 position statement based on the Manchester Consensus Conference. Br J Sports Med. 2013:1–9.
6. Tyler TF, Silvers HJ, Gerhardt MB, Nicholas SJ. Groin Injuries in Sports Medicine. Sport Health: A Multidiscip Approach. 2010;2(3):231–236.
7. Ellsworth AA, Zoland MP, Tyler TF. Athletic Pubalgia and Associated Rehabilitation. Int J Sports Phys Ther. 2014;9(6):774–784.
8. Woodward JS, Parker A, Macdonald RM. Non-surgical treatment of a professional hockey player with the signs and symptoms of sports hernia: a case report. Int J Sports Phys Ther. 2012;7(1):85–100.
9. Meyers WC, Yoo E, Devon ON, et al. Understanding "Sports Hernia" (Athletic Pubalgia): The Anatomic and Pathophysiologic Basis for Abdominal and Groin Pain in Athletes. Oper Tech Sports Med. 2012;20:33–45.
10. Hegedus EJ, Stern B, Reiman MP, Tarara D, Wright AA. A suggested model for physical examination and conservative treatment of athletic pubalgia. Phys Ther Sport. 2013;14(1):3–16.
11. Omar IM, Zoga AC, Kavanagh EC, et al. Athletic pubalgia and "sports hernia": optimal MR imaging technique and findings. Radiographics. 2008;28:1415–1438.
12. Orchard JW, Read JW, Neophyton J, Garlick D. Groin pain associated with ultrasound finding of inguinal canal posterior wall deficiency in Australian Rules footballers. Br J Sports Med. 1998;32(2):134–139. doi: 10.1136/bjsm.32.2.134.
13. Drew MK, Osmotherly PG, Chiarelli PE. Imaging and clinical tests for the diagnosis of long-standing groin pain in athletes. A systematic review. Phys Ther Sport. 2014;15(2):124–129. doi: 10.1016/j.ptsp.2013.11.002.
14. Serner A, Tol JL, Jomaah N, et al. Diagnosis of Acute Groin Injuries: A Prospective Study of 110 Athletes. Am J Sports Med. 2015
15. Candela V, De Carli A, Longo UM, et al. Hip and groin pain in soccer players. Joints. 2021;7:182-187.
16. Mosler AB, Weir A, Eirale C, et al. Epidemiology of time loss groin injuries in a men's professional football league: A 2-year prospective study of 17 clubs and 606 players. Br J Sports Med. 2018;52:292-297.
17. Werner J, Hagglund M, Walden M, Ekstrand J. UEFA injury study: A prospective study of hip and groin injuries in professional football over seven consecutive seasons. Br J Sports Med. 2009;43(13):1036-1040.
18. Elattar O, Choi H, MD, Dilis VD, Busconi B. Groin injuries (athletic pubalgia) and return to play. Sports Health. 2016;8(4):313-323.
19. Drager J, Rasio J, Newhouse A. Athletic pubalgia (Sports Hernia): Presentation and treatment. Arthroscopy. 2020;36(12):2952-2953.
20. Meyers WC, Yoo E, Devon ON, et al. Understanding "sports hernia"(athletic pubalgia): The anatomic and pathophysiologic basis for abdominal and groin pain in athletes. Oper Tech Sports Med. 2012;20:33-45.
21. Schoiten PM, Massimi S, Dahmen N, Diamond J, Wyss J. Successful treatment of athletic pubalgia in a lacrosse player with ultrasound-guided needle tenotomy and platelet-rich plasma injection: A case report. PM & R. 2015;7:79-83.
22. Thorborg K, Hölmich P, Christensen R, Petersen J, Roos EM. The Copenhagen Hip and Groin Outcome Score (HAGOS): development and validation according to the COSMIN checklist. Br J Sports Med. 2011;45(6):478-491.
23. Mehta SP, Fulton A, Quach C, Thistle M, Toledo C, Evans NA. Measurement properties of the Lower Extremity Functional Scale: A systematic review. J Orthop Sports Phys Ther. 2016;46(3):200-216.
24. Justin W. Arner, Ashley Disantis, James P. Bradley, Brian S. Zuckerbraun, Craig S. Mauro. Management of hip and groin pain in American football player. Ann Joint 2017; 2:78
25. Jaspal Ricky Singh, Ryan Roza, Arthur R. Bartolozzi. Platelet Rich Plasma Therapy in an Athlete with Adductor Longus Tendon Tear . UPOJ vol 20, may 20
*26. F Randelli et al. The Collagen-Based Medical Device MD-Tissue Acts as a Mechanical Scaffold Influencing Morpho-Functional Properties of Cultured Human Tenocytes * Cells 2020, 9, 2641*
27. Corrado B. et al. Ultrasound-guided collagen injections in the treatment of supraspinatus tendinopathy: a case series pilot study. Advances in in musculoskeletal diseases and infections. Journal of Biological Regulators and Homeostatic Agents. 2020 May-Jun;34(3 Suppl. 2):33-39.

EVALUATION OF THE EFFECTIVENESS OF A COLLAGEN-BASED MEDICAL DEVICE IN THE INJECTABLE TREATMENT OF GREATER TROCHANTERIC PAIN SYNDROME

A. Fioruzzi[1], M. Mazzoleni[1], L. Verga[2], L. Rahali[2], A. Radaelli[3], F. Randelli[1]

1 – ASST Gaetano Pini – CTO, CAD
2 – ASST Gaetano Pini – CTO, Radiodiagnostics
3 – University of Milan

INTRODUCTION:

Greater Trochanteric Pain Syndrome (GTPS) is a clinical condition characterized by pain in the lateral hip region, often chronic in nature. The primary cause is tendinopathy of the gluteus minimus and medius muscles. Previous ex vivo studies have shown that the use of collagen (COL-I) (GUNA MD-Tissue) stimulates tendon proliferation and healing. The present study aims to evaluate the clinical and radiological effects of peritrochanteric injection treatment with GUNA MD-Tissue in patients with GTPS.

MATERIALS AND METHODS

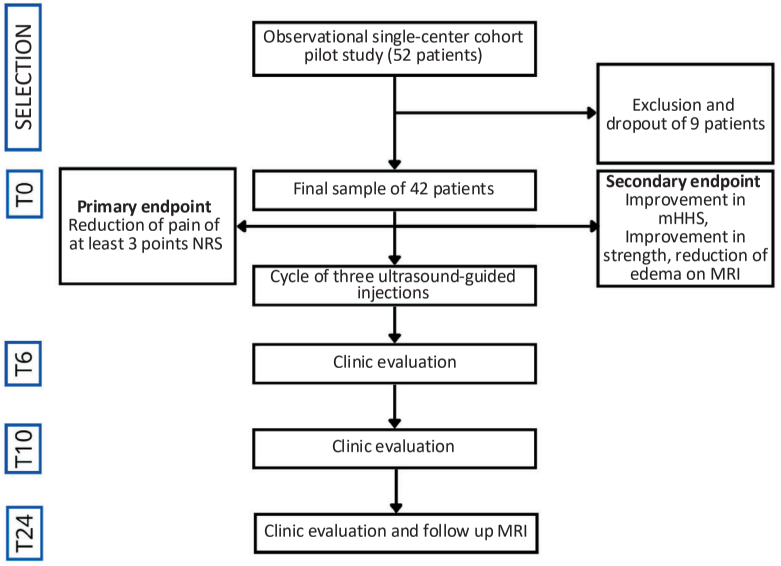

RESULTS:

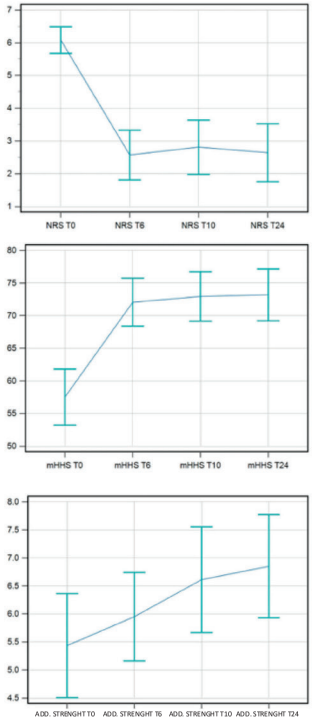

CONCLUSIONS:

Ultrasound-guided peritrochanteric injections of GUNA MD-TISSUE are safe and effective.

LEG - CALF

ISOKINETIC MEDICAL GROUP
FIFA MEDICAL CENTRE OF EXCELLENCE
XXXIII ISOKINETIC CONFERENCE
FOOTBALL MEDICINE
RETURN TO PERFORMANCE
18th, 19th, 20th, April 2026 • Athens, Greece



BIOLOGY FIRST, LOAD LATER: INJECTABLE COLLAGEN PRIMING IN INSERTIONAL TENDINOPATY

BALDASSARRI M, *Clinic-Hospital "Villa Laura", Bologna, Italy*
RICCIARDELLO R, *Clinic-Hospital "Villa Laura", Bologna, Italy*
GHINELLI D, *Clinic-Hospital "Villa Maria", Rimini, Italy*
PERAZZO L, *Private Clinic-Hospital "Gruppioni", Bologna, Italy*
BUDA R, *Private Clinic-Hospital "Gruppioni", Bologna, Italy*

INTRODUCTION AND PURPOSE:

Chronic insertional tendinopathies are characterized by extracellular matrix (ECM) disorganization, altered enthesic biology and impaired adaptation to mechanical loading. Although eccentric rehabilitation represents a cornerstone of treatment, clinical outcomes remain inconsistent in chronic cases, possibly due to an unfavorable biological microenvironment. Injectable collagen has been proposed as a biological strategy capable of supporting collagen synthesis and modulating the ECM, thereby improving tissue readiness to load. The purpose of this study was to compare clinical, functional and ultrasound outcomes of patients with chronic insertional tendinopathies undergoing eccentric rehabilitation **with or without prior ECM priming using injectable porcin collagen (MD-Tissue Guna S.p.A.).**

METHODS:

A prospective controlled cohort study was conducted on 24 patients affected by chronic insertional tendinopathies refractory to at least three months of conservative treatment. Patients were allocated into two groups with **identical anatomical site distribution and equal number of patients per tendon location**, including Achilles insertional tendinopathy, patellar insertional tendinopathy and lateral epicondylitis.

The **collagen group (n = 12)** received a standardized protocol of peritendinous or enthesic injectable collagen priming using **MD-Tissue (2 ml per administration)** prior to rehabilitation, while the **control group (n = 12)** underwent the same standardized eccentric rehabilitation protocol without biological priming. Mechanical loading was initiated only after completion of the priming phase.

Outcome measures included tendon-specific VISA score, pain during load assessed by visual analogue scale (VAS), activity level assessed using the Tegner Activity Scale, time to return to sport, and ultrasound evaluation. **Return to sport was defined as return to full training without pain, excluding competitive match play**, in accordance with contemporary return-to-sport frameworks. Ultrasound assessment included enthesis thickness and **enthesic vascular activity evaluated using the semi-quantitative Power Doppler score according to Öhberg et al. (0–4)**. Assessments were performed at baseline and at a minimum follow-up of 12 weeks.

RESULTS:

At follow-up, the collagen group demonstrated greater improvements in VISA score (from 52 ± 9 to 78 ± 8) compared with the control group (from 53 ± 8 to 65 ± 10). Pain during mechanical loading decreased more markedly in the collagen group (VAS from 6.8 ± 1.1 to 2.3 ± 1.2) than in controls (from 6.6 ± 1.0 to 3.9 ± 1.4). Activity level assessed by the Tegner scale at follow-up was closer to pre-injury values in the collagen group (6.0 ± 1.1 vs pre-injury 6.5 ± 1.2) compared with the control group (5.2 ± 1.3 vs pre-injury 6.4 ± 1.0).

Ultrasound evaluation showed a greater reduction in enthesic vascular activity in the collagen group, with median **Öhberg Power Doppler score** decreasing from 3 to 1, compared with a reduction from 3 to 2 in the control group. Mean enthesis thickness decreased from 6.1 ± 0.8 mm to 5.4 ± 0.7 mm in the collagen group, while remaining largely unchanged in controls (6.0 ± 0.7 mm to 5.8 ± 0.8 mm). No serious adverse events were observed.

CONCLUSIONS:

Extracellular matrix priming with injectable porcin collagen **MD-Tissue (2 ml)** prior to eccentric rehabilitation appears to enhance clinical outcomes, improve tolerance to mechanical loading and facilitate earlier return to full training in patients with chronic insertional tendinopathies. The observed reduction in enthesic vascular activity, quantified using the Öhberg Power Doppler score, supports a modulatory effect on pathological biological activity rather than structural regeneration. This **biology-first, load-later** strategy may optimize mechanotherapy effectiveness independently of the specific anatomical site. Further randomized studies with longer follow-up and larger cohorts are warranted.

GREATER CLINICAL IMPROVEMENT WITH COLLAGEN PRIMING

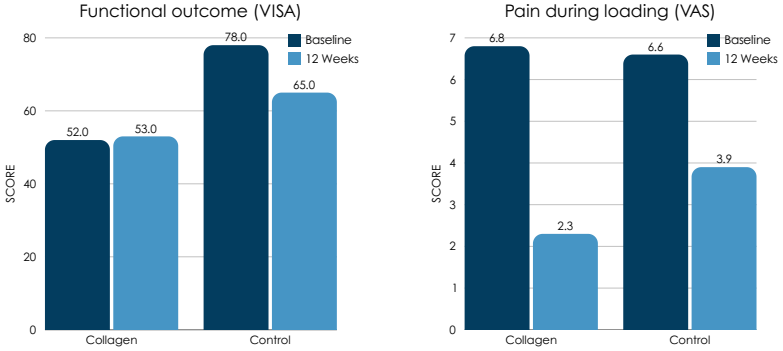

Changes in tendon-specific VISA score (A) and pain during load assessed by visual analogue scale VAS) (B) at baseline and at 12-week follow-up in the collagen and control groups.

ECM PRIMING IMPROVES FUNCTION, REDUCES PAIN AND ENHANCES TOLERANCE TO MECHANICAL LOADING

BIOLOGICAL ULTRASOUND RESPONSE

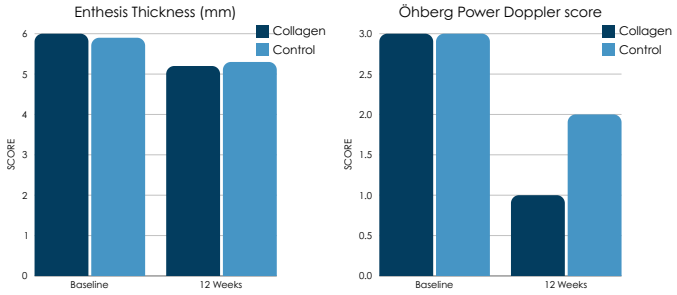

The collagen group showed a greater reduction in enthesic vascular activity (Öhberg score), suggesting modulation of pathological tendon biology. Structural changes were less pronounced.

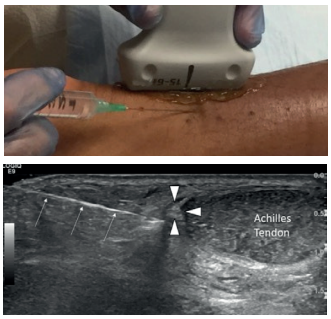

Targeted biological priming of the Achilles enthesis.
Ultrasound-guided peritendinous injection of collagen at the Achilles tendon insertion. Real-time imaging ensures accurate delivery to the enthesis, the key site of pathological extracellular matrix disorganization.

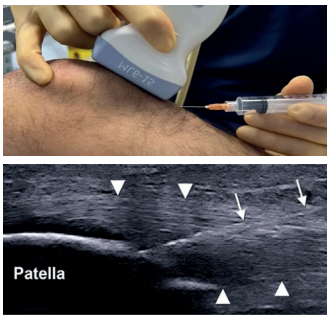

Targeted biological treatment of patellar tendinopathy.
Top: ultrasound-guided collagen injection at the patellar tendon insertion. Bottom: ultrasound image demonstrating typical tendinopathic changes, including hypoechoic areas and matrix disorganization (arrowheads), representing the biological target of treatment.

REFERENCES:

1. Randelli F, Sartori P, Carlomagno C, Bedoni M, Menon A, Vezzoli, Sommariva M, Gagliano N. The Collagen-Based Medical Device MD-Tissue Acts as a Mechanical Scaffold Influencing Morpho-Functional Properties. Cells 2020 Dec; 9(12): 2641.
2. Baldassarri M, Ricciardello S, Ghinelli D, Perazzo L, Buda R. Porcine Collagen Injection Therapy Affects Proximal Hamstring Tendinopathy in Athletes by Reducing Time to Return to Sport. Sports (Basel). 2025 Oct 10;13(10):359.
3. Ackermann PW, Renström P. Tendon vascularity revisited: a narrative review. British Journal of Sports Medicine, 2012;46(3):173–178.

SIMFER
SOCIETÀ ITALIANA DI MEDICINA FISICA E RIABILITATIVA
The Italian Society of Physical and Rehabilitation Medicine

52° CONGRESSO NAZIONALE SIMFER
PADOVA 6 | 9 OTTOBRE 2024

EFFECTIVENESS OF INJECTABLE COLLAGEN IN PAIN FROM AMPUTATION NEUROMA: A CASE STUDY

INTRODUCTION

Post-amputation pain is a common condition that significantly affects patients' quality of life [1]. It is sometimes associated with the presence of a neuroma, which is typically diagnosed based on the neuropathic characteristics of the pain, a positive Tinel's sign, and occasionally the onset of phantom limb pain upon mechanical stimulation of the neuroma [2]. Regarding the treatment of neuroma-related pain, the literature highlights the limited efficacy of proposed conservative therapies. Based on the pathophysiological mechanisms underlying this type of pain, we hypothesized that the use of injectable medical devices based on collagen could represent a promising alternative.

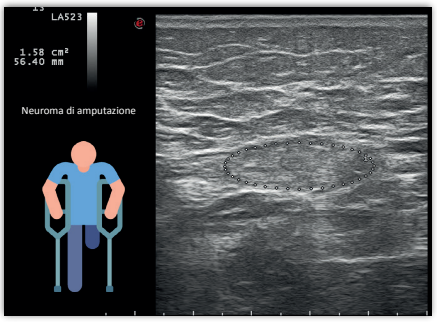

MATERIALS AND METHODS

We describe the case of an 87-year-old man with a traumatic left transfemoral amputation since the age of 7, who had been experiencing neuroma-related pain for several months, which was refractory to analgesic therapy and prevented the use of his prosthesis. The patient underwent local peri-neuronal injectable treatment with collagen (Guna, MD-NEURAL, total volume 4 ml) in two closely spaced sessions, under ultrasound guidance.

The primary outcome was the change in pain, measured using three validated questionnaires: 1. Numerical Rating Scale (NRS), 2. McGill Pain Questionnaire–Short Form (MPQ-sf), 3. Neuropathic Pain Symptom Inventory (NPSI).

A change exceeding the Minimal Clinically Important Change (MCIC) threshold was considered clinically significant [3]. The neuroma area was also monitored ultrasonographically to detect any treatment-related changes. Evaluations were conducted one month before treatment (T-1), immediately before the first treatment (T0), immediately after the second treatment (T1), and one month after the second treatment (T2).

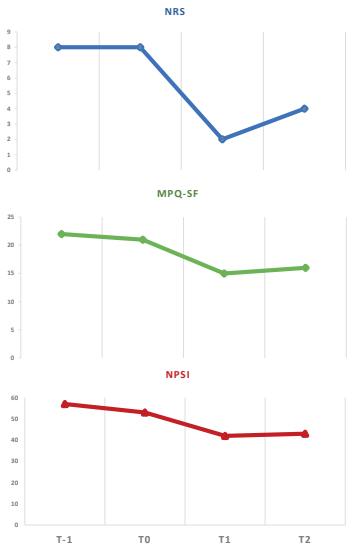

RESULTS

No adverse events occurred. There was a notable improvement in the NRS score between T0 and T1 (from 8/10 to 2/10), and the benefit was maintained one month after the last injection (T2). Similarly, the MCIC was exceeded between T0 and T1 for both the NPSI and MPQ-sf scores. In addition to the reduction in pain intensity, paresthesias improved, while the allodynic component remained unchanged. The patient resumed the use of the limb prosthesis and walking. Ultrasound monitoring of the neuroma area did not show substantial changes across the four evaluations.

CONCLUSIONS

The results demonstrate a clinically significant reduction in pain from amputation neuroma. This safe, minimally invasive, and well-tolerated treatment may represent a valid alternative, especially in patients with multiple comorbidities and in the elderly, who constitute the majority of amputees in Western countries. A potential mechanism of action may involve collagen's ability to reduce peripheral pro-inflammatory factors, whereas a purely mechanical effect appears less likely. The treatment appears worthy of further investigation in larger studies.

Bibliography

[1] Hsu E, Cohen SP. Postamputation pain: epidemiology, mechanisms, and treatment. *J Pain Res*. 2013;6:121-36.
[2] Davis RW. Phantom sensation, phantom pain, and stump pain. *Arch Phys Med Rehabil*. 1993 Jan;74(1):79-91.
[3] C. Malfitano, A. Rossetti, S. Scarano, C. Malloggi, and L. Tesio, "Efficacy of Repetitive Transcranial Magnetic Stimulation for Acute Central Post-stroke Pain: A Case Study," *Front Neurol*, vol. 12, 2021.

Malfitano C.[1,2], Dallavalle J.[2,3], Casto E.[3], Agnello R.[2]
[1]Ricercatore (RTD-B) Dipartimento di Scienze Biomediche per la Salute, Università degli Studi di Milano
[2]ASP IMMeS e Pio Albergo Trivulzio, Milano
[3]Scuola di Specializzazione in Medicina Fisica e Riabilitativa, Università degli studi di Milano

Azienda di Servizi alla Persona
Istituti Milanesi Martinitt e Stelline e Pio Albergo Trivulzio

UNIVERSITÀ DEGLI STUDI DI MILANO

FOOTBALL MEDICINE
BRIDGING sCIENCE AND PRACTICE 25th, 26th, 27th May 2024 - MADRID, Spain

ISOKINETIC MEDICAL GROUP

IDEAL PATH OF FUNCTIONAL RECOVERY FOR RETURN TO PLAY ASSOCIATED WITH COLLAGEN MD-TISSUE IN PADEL PLAYER AFFECTED BY QUADRICEPS TENDINOPATHY

Cera A, Bonsanto F
Isokinetic Medical Group, FIFA Medical Centre of Excellence, Bologna Italy

Introduction

Ideal path in a rehabilitation protocol for chronic tendinopathy is to have a linear improvement trend, without recurrent exacerbations.
MD-Tissue is a type of injectable collagen that works by inducing healing processes thanks to its direct action on fibroblasts1. In this case the choice was dictated by the fact that the foreign body present in the tendon prevents the use of ESW that we classically use in these rehabilitation protocols.

Case report

The subject of our study is a 50-year-old (173kg; 73kg) practicing Padel (Tegner 4). Due to a trauma that occurred in early age, in the patient's quadriceps tendon there is a fragment of glass that passes through half of its thickness (left knee). Because of this, the patient frequently presented symptomatic exacerbations with sporting activity limitation. After the last exacerbation he came to our observation.
Before starting the rehabilitation, process Imaging tests were performed: MRI which highlighted the known hypointense formation of approximately 18 mm at the distal insertion of the quadriceps tendon, attributable to a foreign body, Ultrasound Scan showed a thickening of the quadriceps tendon, positive at PD.
The functional limitation occurred in his daily life, especially when descending stairs and during a run, reasons for which he stopped sporting activity.
The therapeutic protocol began with the administration of 6 phials of MD-Tissue, two intratendinous loco-regional doses per week, using a 0.6 mm needle.

The procedure did not require any stop of physical activity, so the rehabilitation process started at the same time. The monitoring of the clinical/functional progress was carried out thanks to **2 Isokinetic Tests** and **2 Movement Analysis Test (MAT)**, the first before starting the Neuromotor Training (NMT) in the Green Room, the other one at the end of the NMT.
After 15 weeks of rehabilitation and 12 NMT sessions, the new MAT on the left leg improved with a result of 74/100. This could be attributed to improved control of the pelvis and trunk, although a persistent tendency towards dynamic valgus remained. The Weight Shift on the Drop Vertical Jump was only 1% of the vGFR (Vertical Ground Force Reactions) calculated on the right limb.
In conclusion, the patient was subjected to on field test, the Illinois Agility Test3 (IAGT, test). This test takes place on a very small area (5 m x 10 m), delimited by cones. During the test are performed changes of direction (COD), sprints, accelerations, decelerations, and everything is timed to evaluate the type of performance. Our patient concluded the test without any symptoms and with a good performance (18.80 seconds, that corresponds to an average time).
The patient was able to Return to Play his sport, at the same previous level, after 17 weeks of rehabilitation and 3 MD-Tissue injections, with no pain symptoms.

Conclusions

Collagen was a useful therapeutic support that compensated the ESW, normally used in our protocols; furthermore, the use of Collagen does not imply the suspension of sporting activity.
MAT TEST and ISOKINETIC TEST were needful to obtain a linearly improvement in rehab protocol. In fact, despite the final score of the MAT being 74/100, particular emphasis should be given to the resetting of the Weight Shift between the two lower limbs which appears to be one of the main prerequisites for tendon overload of the extensor apparatus.

Figure 1



Figure 2

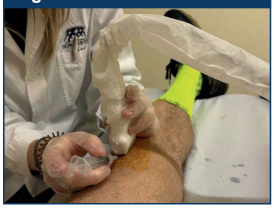

Figure 3

Session	N	Treatment
Gym	12	First 3 weeks after the first injection: we performed physical therapies (laser therapy, US) to reduce the painful symptoms, then muscle relaxation with manual therapy on femoris quadriceps, hamstrings, stretching of the posterior kinetic chain (CCP). After we proceeded with functional strength of the entire lower limbs, working in synergy, focusing on the stabilizing muscles of the hip, knee and ankle, first in isometry and progressively eccentric strenght for quadriceps working below the pain threshold, hip abductors and external rotators (particularly gluteus medius), hamstrings, triceps surae, ankle plantar and dorsal flexors, aerobic work on an exercise bike.
TI	1	After 4 weeks of rehabilitation, an isokinetic test was performed which revealed an extensor deficit of 35% (strength) and 44% (endurance).
Gym	8	With the results of the Isokinetic test the second part of the rehabilitation was focused on eccentric strengthening by working in an Open Kinetic Chain (OCK), then in a Closed Kinetic Chain (CKC). We work also on Core stability and pelvis control, proprioception and aerobic work
TI	1	After 9 weeks of rehabilitation: at the control Isokinetic Test the deficit between the two lower limbs was significantly reduced, the extensors showed 19% (strength) and 8% (endurance).
MAT	1	The result of test was 64/100 that was considered as non-optimal, Weight Shift on the Drop Vertical Jump was 28% on the right lower limb.
NMT	12	Thanks to the results that emerged from the MAT, Neuromotor Training in the Green Room was defined, using real time Biofeedback on a Video wall and a Force Plate in each session. The exercises were performed to the knee stabilization (dynamic valgus), functional strengthening exercises of the external rotators, extensors, hip abductors², core stability exercises, exercises for pelvis and trunk control (functional strengthening of the erector spinae muscles). Finally, to reduce the Weight Shift that was 28% on the right lower limb, we focused on progressive advanced plyometry, working on the symmetry of the plantar support during the landing phase.

Figure 4

	MAXIMUM STRENGHT (Nm) 4 repetitions at 90°/s		RATIO Flexor/Extensor(%)	ENDURANCE (J) 20 repetitions at 180°/s		RATIO Flexor/Extensor (%)
	Extensor	Flexors	Strenght	Extensor	Flexors	Resistance
INJURED LEG (LEFT)	132	89	67%	1991	1164	58%
NON-INJURED LEG (RIGHT)	162	97	60%	2157	1100	51%
DEFICIT (%)	19%	8%		8%	-6%	

Figure 5

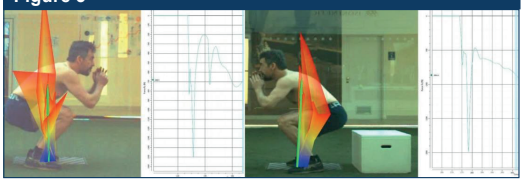

1st MAT before NMT in GR. Average initial peak of vGFR (Ground Forcereactions) right side (not injured limb)1870 N.Average initial peak of vGFR (Ground Force Reactions) left side (injured limb) **1311 N**.

Figure 6

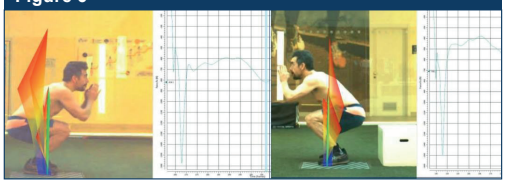

2nd MAT after NMT in GR. Average initial peak of vGFR (Ground Force Reactions) right side (not injured limb): **1524 N**. Average initial peak of vGFR (Ground Force Reactions) left side (injured limb): **1517 N**.

Figure 7

LEFT LEG (injured)	1st MAT	2nd MAT
Mono-podalic Squat	6	7
Drop Jump	3	4
Lateral Landing	5	6
Deceleration	8	7
Single Leg Hop	6	6
Cut Manoeuvre	4	7
TOTAL SCORE	64	74
Weight Shift	28%	1%

Figure 8



References

1. Filippo Randelli,1 Alessandra Menon,2 Alessio Giai Via,1 Manuel Giovanni Mazzoleni,1 Fabio Sciancalepore,2 Marco Brioschi,1 and Nicoletta Gagliano3,*. Effect of a Collagen-Based Compound on Morpho-Functional Properties of Cultured Human Tenocytes. MDPI: 2018 Dec; 7(12): 246.
2. Crossley KM, Zhang W-J, Schache AG, Bryant A, Cowan SM. Performance on the Single-Leg Squat Task Indicates Hip Abductor Muscle Function. Am J Sports Med 2011; 39:866-873
3. Hachana, Younes; Chaabène, Helmi; Nabli, Mohamed A.; Attia, Ahmed; Moualhi, Jamel;Farhat, Najiba; Elloumi, Mohamed. Test-Retest Reliability, Criterion-RelatedValidity, and Minimal Detectable Changeof the Illinois Agility Test in Male TeamSport Athletes : The Journal of Strength &Conditioning Research. Journal of Strength and Conditioning Research 27(10):p 2752-2759, October 2013

ISOKINETIC
FIFA MEDICAL CENTRE OF EXCELLENCE



COLLAGEN INJECTION TREATMENT IN MEDIAL GASTROCNEMIUS MUSCLE INJURY

Cristiano Fusi[1], Mirko Mutti[2]

1. Head of the Specialist Rehabilitation Unit of the Istituti Clinici Zucchi in Monza and of the Rehabilitation and Sports Medicine Centre of Zucchi Wellness Clinic Gruppo San Donato, Via Bartolomeo Zucchi, 24, 20900 Monza, MB, Italy. Istituti Clinici Zucchi, Monza, Italy.
2. Head of Physical and Rehabilitation Medicine at the Istituti Clinici Zucchi di Monza Gruppo San Donato, Via Bartolomeo Zucchi, 24, 20900 Monza, MB Italy.

INTRODUCTION:

Muscle injuries are among the most frequent injuries occurring in the sports community, and those to the gastrocnemius muscle, such as the one in our clinical case, are some of the most common injuries.
In this case study, an in-depth examination of injuries was carried out, including description, causes and physiology of healing, classification, physical and instrumental therapies, and rationale for the use of injectable collagen to speed up the repair and functional healing of the muscle and the return to sporting activity. Collagen is the most abundant protein in the body and a constituent of soft tissues: tendons, ligaments, muscles.



OBJECTIVE:

To share, by using a clinical case, the epidemiology, aetiology, diagnostic criteria, and therapeutic interventions for the gastrocnemius muscle injury.

MATERIALS AND METHODS:

The patient enrolled was a 24-year-old male professional cyclist who came to our consultation for stabbing pain in the posterior left thigh arose during daily training. He was suspected of GRADE I°/II° GASTROCNEMIC LESION due to strain and showed local oedema, muscle tension, stiffness, pain on locoregional palpation and during mobilisation and contraction. After ultrasound confirmation of a grade I° muscular lesion in the 3° medial gastrocnemius, it was decided to proceed with functional rest, 8 sessions of Human TECAR therapy on alternate days and local collagen injections.

After 7 days, the patient underwent 3 ultrasound-guided injections of collagen MD-Muscle (1 vial of 2ml) at weekly intervals. The injections were administered intramuscularly at the level of the lesion in the medial gastrocnemius, with a 22G x 3.50'' – 0.7mm x 90mm needle and by ultrasound approach. The pain assessment scale was the VAS (Visual Analogue Scale) of initial and final pain at one month after the end of the injection cycle. Follow-up pain assessment at 3 and 6 months was also useful.
In terms of pain reduction, the outcome values were assessed with VAS scale from initial point 8 (T0), to intermediate point 4 (T1), to final point 0 (T2). Follow up were done at 3 months (T3) and 6 months (T4).

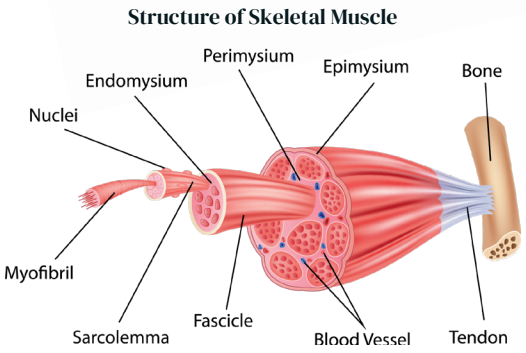

RESULTS:

The patient reported progressive improvement in pain and function of the affected limb after the treatment with physical therapy and rest combined with Collagen injections.
Three weeks after the injury occurred ultrasound scans showed no trace of scarring, which could have caused discomfort in the performance and resumption of professional sporting activity. The patient therefore resumed his athletic activity. The perfect *restitutio ad integrum* accelerated recovery time, avoiding excessive retraining of the muscle during its daily physiological movement. Collagen allowed to contain muscular scarring, which usually prevents physiological contraction and release movement.

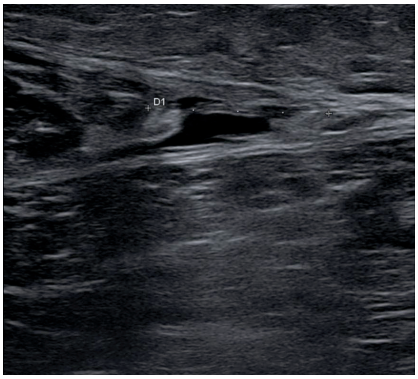

Ultrasound imaging of Medial Gastrocnemius grade I/II with local oedema and thinning of muscle fibers.

CONCLUSIONS:

The injection treatment with **Guna collagen MD-MUSCLE** is a useful, safe, and easy-to-use reparative treatment. Collagen injections can be used in combination with physical therapies. In addition, the synergic use with TECAR therapy methodology can accelerate the reabsorption of the perilesional oedema, facilitating targeted deposition of collagen.
MD-MUSCLE significantly reduced pain, had antioxidant and anti-inflammatory activity and promoted homeostasis, remodelling and tissue repair, by acting as an active scaffold at the level of the extracellular membrane. Further studies will be necessary to prove effectiveness on a wider number of cases.

REFERENCES:

1. Maffulli N, Oliva F, Giai Via A, Frizziero A, Melegati G, Nanni G, Valent A, et al. Muscle Injuries: A Brief Guide to Classification and Management, Transl Med UniSa. 2014 Sep 1; (12):14-8.
2. Randelli F, Menon A, Giai Via A, et al, Effect of a Collagen-Based Compound on Morpho-Functional Properties of Cultured Human Tenocytes. Cells. 2018 Dec 6;7(12):246.
3. Järvinen TA, et al, Regeneration of injured skeletal muscle after the injury. Muscles Ligaments Tendons J. 2014 Feb 24;3(4):337-45.

KNEE

SIOT 2025 ROMA
www.congressosiot.it
108° CONGRESSO NAZIONALE DELLA SOCIETÀ ITALIANA DI ORTOPEDIA E TRAUMATOLOGIA
ROMA 6-8 NOVEMBRE Centro Congressi Rome Cavalieri Waldorf Astoria

MENISCUS TRANSPLANT WITH ALLOGRAFT AND AUGMENTATION WITH COLLAGEN SCAFFOLD: *A CASE REPORT*.

Luca Ruosi Ortopedia IRCCS Humanitas Research Hospital Rozzano Milan Italy
Andrea Antonio Maria Bruno Department of Orthopedics, IRCCS Humanitas Research Hospital, Milan
Enrico Arnaldi Director of Orthopedics, IRCCS Humanitas Research Hospital, Milan
Massimo De Donato Department of Orthopedics, IRCCS Humanitas Research Hospital, Milan
Marco Basso Department of Orthopedics, IRCCS Humanitas Research Hospital, Milan

INTRODUCTION:

Meniscus injuries have an incidence of approximately 60 cases per 100,000 inhabitants. They are more common in young people due to knee sprains or in older people due to degenerative conditions. The gold standard for treating meniscus injuries is arthroscopic partial meniscectomy (APM). The need for meniscal allograft transplantation (MAT) after an APM varies depending on age, the amount of meniscus removed, and functional requirements. Cryopreserved cadaver grafts contain less type 1 collagen and less collagen fiber organization than in vivo menisci. Early failure (within 12 months) of MAT has been reported in the literature in the range of 5% to 11%. Type 1 collagen is a safe and effective biopolymer. It is one of the injectable medical devices used as orthobiologics: it promotes homeostasis and tissue repair. In vitro, it demonstrated tissue regenerative activity and the properties of a liquid scaffold of the extracellular matrix.

MATERIALS AND METHODS:

A patient with medial overload and extrusion of the medial meniscal remnant following APM was treated with MAT, using the all-soft-tissue technique.
During its preparation, the graft was treated with infiltration of MD-TISSUE collagen medical device (Guna S.p.A., Italy). The patient was then clinically reevaluated at 1, 6, and 12 months, with follow-up MRI at 12 months.

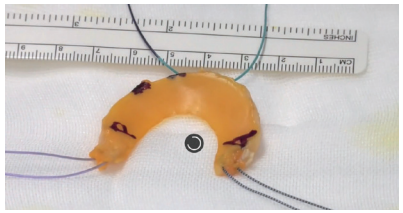
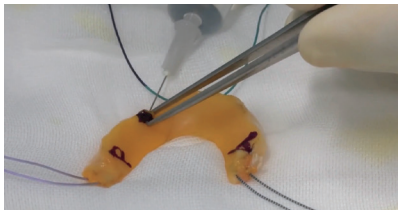

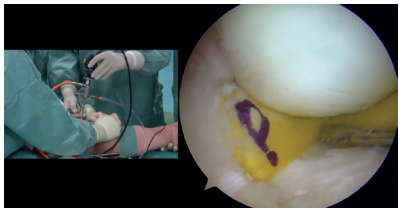

RESULTS:

At 12 months, no adverse effects had occurred. No technique failure was observed. On MRI, the graft showed good integration. All clinical scores evaluated showed improvement greater than the MCID (minimal clinical important difference).

DISCUSSION:

Given the histological structure of meniscal fibrocartilage and the loss of type I collagen that occurs in tissue harvested and stored for use as grafts, the use of MD-TISSUE is a valid option for restoring its content, with the aim of increasing the likelihood of integration.

CONCLUSIONS:

The use of MD-TISSUE, containing type I collagen, is a safe and cost-effective option for providing biological stimulation to meniscal fibrocartilage allografts, with the aim of improving their biomechanical properties. However, larger studies are needed to demonstrate its clinical benefit.

BIBLIOGRAPHY:
1. Wang H. A Review of the Effects of Collagen Treatment in Clinical Studies. Polymers (Basel). 2021 Nov 9;13(22)
2. Randelli et al. Effect of a Collagen-Based Compound on Morpho-Functional Properties of Cultured Human Tenocytes. Cells 2018
3. Randelli et al. The Collagen-Based Medical Device MD-Tissue Acts as a Mechanical Scaffold Influencing Morpho-Functional Properties of Cultured Human Tenocytes Cells

SIOT 2024 ROMA
www.congressosiot.it
107° CONGRESSO NAZIONALE DELLA SOCIETÀ ITALIANA DI ORTOPEDIA E TRAUMATOLOGIA
Roma 29-31 Ottobre Centro Congressi Rome Cavalieri Waldorf Astoria

INJECTABLE TREATMENT WITH COLLAGEN FOR PATELLAR TENDINOPATHY. A CASE REPORT.

DR. PAOLO BORELLI
Medical Director Orthopaedics and Traumatology U.O.C Orthopaedics Bentivoglio IRCSS Istituto Ortopedico Rizzoli

INTRODUCTION:
Acute and chronic inflammatory tendon disorders are common in individuals exposed to functional overload, unhealthy work habits, poor lifestyle choices, or underlying pathological conditions. The need to repair the altered tendon structure may involve the use of injectable collagen due to its regenerative effectiveness.

MATERIALS AND METHODS:
The case involves a 50-year-old male patient, an amateur tennis player who participates periodically in competitive matches. During clinical evaluation, the patient reported having suspended sports activity for one month due to the onset of pain in the anteromedial aspect of the right knee. After an unsuccessful one-week course of NSAIDs, an MRI was prescribed. The imaging showed an intact capsuloligamentous apparatus of the knee, with thickening of the proximal portion of the patellar tendon (11 mm), delamination of the external margin with a focal lesion measuring 2x1x13 mm, and delamination at the insertion of the quadriceps tendon on the patella. The patellar tendon, while continuous on palpation and functional testing, appeared edematous and painful on pressure. A treatment cycle of injective therapy with Guna MD-TISSUE collagen was proposed, consisting of 5 weekly injections with 4 ml of MD-TISSUE (2 vials), performed manually along the course of the tendon, targeting 3 symmetrical points on each side, using a 21G - 13 mm needle.

COLLAGEN

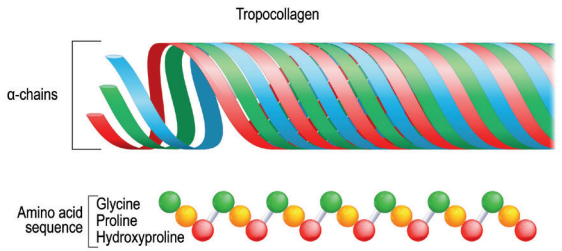

RESULTS:
After three injections, the patient reported absence of pain during stair climbing and walking, with a reduced VAS score. At the end of the treatment cycle, symptoms had resolved completely. Ultrasound examination showed a minimal residual effusion and slight thickening of the subcutaneous loose connective tissue in the pretibial area, with mild thickening of the tendon at its insertion, without discontinuity or evidence of tearing lesions.

DISCUSSION:
The injective therapy was well tolerated, with easy administration, convenient frequency (once every 7 days), and absence of adverse effects.

CONCLUSION:
The case was treated solely with injections to assess their effectiveness. Functional recovery is the strongest evidence supporting the efficacy of this therapy. The ultrasound examination performed at the end of treatment confirmed tissue repair of the lesion. Injective therapy with MD-TISSUE is easy to administer and, for more superficial tendon structures, does not require ultrasound guidance.
It can be stated that Collagen may represent a cost-effective and reparative treatment option.

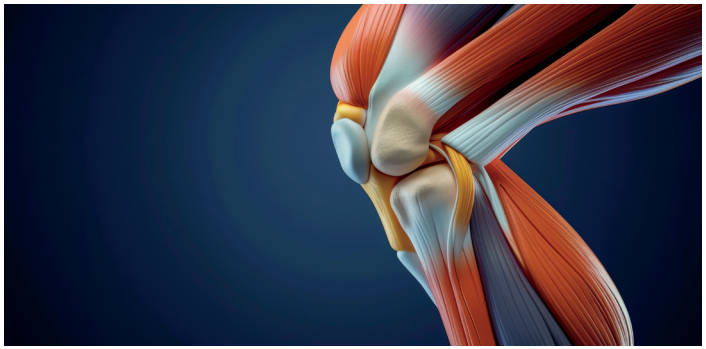

BIBLIOGRAPHY:
1. Randelli F, Sartori P, Carlomagno C, Bedoni M, Menon A, Vezzoli E, Sommariva M, Gagliano N. The Collagen-Based Medical Device MD-Tissue Acts as a Mechanical Scaffold Influencing MorphoFunctional Properties of Cultured Human Tenocytes. Cells. 2020 Dec 8;9(12):2641.
2. Randelli F, Menon A, Giai Via A, Mazzoleni MG, Sciancalepore F, Brioschi M, Gagliano N. Effect of a Collagen-Based Compound on Morpho-Functional Properties of Cultured Human Tenocytes. Cells. 2018 Dec 6;7(12):246.
3. Figueroa D, Figueroa F, Calvo R. Patellar Tendinopathy: Diagnosis and Treatment. J Am Acad Orthop Surg. 2016 Dec;24(12):e184-e192.

3rd ANNUAL MEETING
SIAGASCOT
BARI
21-23 MARCH 2024
THE NICOLAUS HOTEL

PAINFUL KNEE PROSTHESIS: CAN INJECTABLE COLLAGEN HELP US?

CASE REPORT

GIACOMO PLACELLA
Vita-Salute San Raffaele University
San Raffaele Hospital Institute for Treatment and Research, Milan

I.R.C.C.S. Ospedale San Raffaele
San Donato Group

INTRODUCTION

Injectable collagen in the treatment of tendinopathy, arthropathy, inflammatory diseases and painful scarring has been extensively studied and is widely used in clinical practice. The safety and success of these treatments has enabled an extension of its indications to other unusual situations such as excessive tendon and ligament tension.

METHODS

A 55-year-old patient with a knee prosthesis, after the first few weeks when the acute phase had passed, experienced medial pain if the two knees were in contact, especially in his preferred lateral position when sleeping at night. The X-ray showed, in addition to the obvious malposition of the tibial plateau which protruded medially by approximately 2mm, an initial calcification at the insertion of the medial collateral, probably due to chronic inflammation. During a clinical examination the patient reported that the site of pain was not precisely at the palpatory marker of the protruding tibial plateau, but instead at the proximal insertion of the medial collateral, therefore at a site at some distance from the implant and extracapsular. The use of GUNA MD-Tissue collagen was therefore recommended, administered in 5 x 4ml injections at one-month intervals, to be performed at the proximal insertion of the medial collateral.

RESULTS

There was a gradual but continuous reduction in pain: the patient was already feeling huge benefits after the third session of injection. The value on the VAS scale decreased from 7 to 2, and no reactions or adverse events were reported at the six-month follow-up.

DISCUSSION

Many studies (Randelli F. et al.) have shown that injectable collagen can affect the human collagen turnover pathway and facilitate the process of fibroblast migration. Specifically, the injectable compound seems able to enhance the expression of an inhibitor gene of some metalloproteases (MMP-1, MMP-2) responsible for collagen degradation. The increased gene expression occurred after the first 24 hours, with an up-regulation after 72. The increase in collagen in the ligaments therefore results from the inhibition of its degradation by specific proteases.

CONCLUSIONS

Injectable collagen has enabled us to relieve painful symptoms caused by malpositioning of prostheses associated with excessive tension in the medial collateral, which would otherwise require replacement of the prosthesis.

COLLAGEN FORMATION

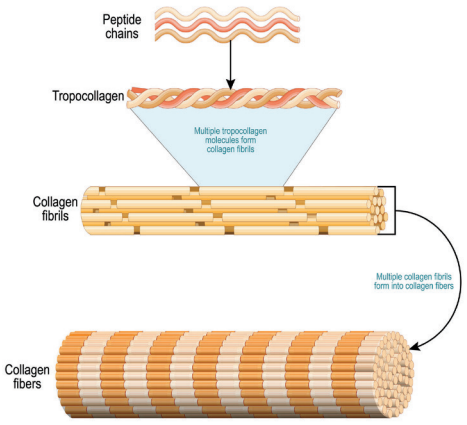



2-MONTH POST-OPERATIVE X-RAY SHOWS MEDIAL LATERAL DEFECT

REFERENCES:

1. Randelli F, Sartori P, Carlomagno C, Bedoni M, Menon A, Vezzoli E, Sommariva M, Gagliano N. The Collagen-Based Medical Device MD-Tissue Acts as a Mechanical Scaffold Influencing Morpho-Functional Properties of Cultured Human Tenocytes. Cells. 2020 Dec 8;9(12):2641.
2. Randelli F, Menon A, Giai Via A, Mazzoleni MG, Sciancalepore F, Brioschi M, Gagliano N. Effect of a Collagen-Based Compound on Morpho-Functional Properties of Cultured Human Tenocytes. Cells. 2018 Dec 6;7(12):246..

POSTER NO.
58

SIMFER
SOCIETÀ ITALIANA DI MEDICINA FISICA E RIABILITATIVA
The Italian Society of Physical and Rehabilitation Medicine

TENDONITIS OF THE BICEPS FEMORIS MUSCLE TREATED WITH COLLAGEN-BASED MESOTHERAPY

Laura Laiosca[1], Brambilla Rossana[1], Valeria Rivolta[1], Carlo Domenico Ausenda[1], Laura Perucca[2]

1. U.O.C. Specialist Rehabilitation, San Carlo Borromeo Hospital - ASST Santi Paolo Carlo, Milan, Italy
2. IRCCS Istituto Auxologico Italiano, Department of Biomedical Science for Health-University of Milan, Milan, Italy

Introduction The tendon is a fibrous connective tissue that enables a muscle to fit onto a bone; it is mainly made up of collagen fibres that give it its high strength and, to a lesser extent, elastin fibres that give it its minimal elasticity. Tendonitis is an inflammation of the tendon that causes pain and local swelling, if this condition is not treated it can damage the fibres that comprise the tendon.
Therapeutic approaches include:

- injectable corticosteroids, oral and topical NSAIDs
- physical therapies (laser, tecar, ultrasound)

The aim of the study is to share the aetiology, diagnostic criteria and innovative therapeutic interventions based on injectable collagen as an option to the usual approaches through the management of a clinical case.

Materials and Methods The patient identified for the study is a 75-year-old woman, who underwent surgery on 12/06/2018 for a right total knee replacement implant, resulting from gonarthrosis. A few years after the surgery, the patient began to complain of pain in the postero-lateral section of her right knee, even at night. Upon physical examination, she presented pain on palpation at the distal insertion of the biceps femoris muscle and along its course for about 4-5 cm cranially.
The ultrasound confirmed a picture of tendinitis in the hamstring muscle. The patient underwent an injection cycle with collagen MD-TISSUE, a cycle of 6 sessions at weekly intervals. During the procedure, a 13 mm 26G needle was inserted freehand at a depth of 2.5 mm. Collagen is the most abundant protein in the body and is the main component of soft tissues, tendons, ligaments and muscles. In this case report, the use of injectable collagen via mesotherapy allowed the tendon to be supplemented of its main element in a non-invasive and easily managed outpatient approach.

Figure 1: *Ultrasound of the posterior knee region*

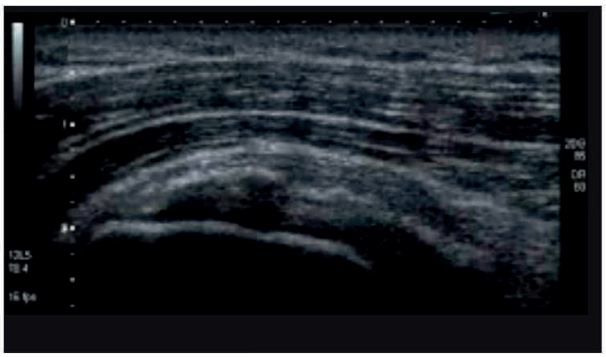

Figure 2: *Triple helix collagen*

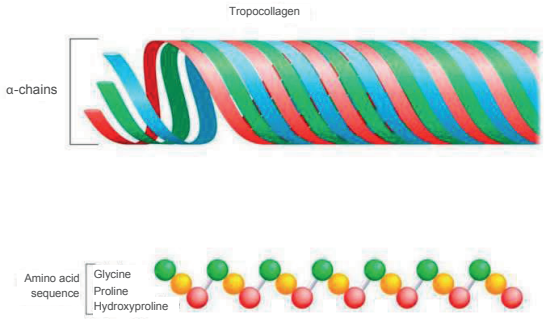

Results The patient reported progressive improvement in both subjective and objective pain after treatment with collagen. Pain was assessed with the VAS scale at TO and T1, i.e. at 1 week after the last injection. Assessing this pain scale showed an improvement in symptomatology from a VAS at TO of 7 to a VAS at T1 of 2.
Conclusions: Periarticular injection treatment with collagen MD-TISSUE, a class III medical device, is a useful, safe and easy-to-use restorative and regenerative solution. Collagen, acting as a bio-scaffold at the level of the extracellular membrane, significantly reduced pain, enhancing the anti-inflammatory activity. It also led to a reduction in oedema, promoting the realignment of fibres, the remodelling of damaged tissue and tissue repair.

Conclusions

Periarticular injection treatment with collagen MD-TISSUE, a class III medical device, is a useful, safe and easy-to-use restorative and regenerative solution. Collagen, acting as a bio-scaffold at the level of the extracellular membrane, significantly reduced pain, enhancing the anti-inflammatory activity. It also led to a reduction in oedema, promoting the realignment of fibres, the remodelling of damaged tissue and tissue repair.

References
• Randelli F, Menon A, Giai Via A, et al, Effect of a Collagen-Based Compound on Morpho-Functional Properties of Cultured Human Tenocytes. Cells. 2018 Dec 6;7(12):246.
• Randelli F, Sartori P, Carlomagno C, Bedoni M, Menon A, Vezzoli E, et al. The Collagen-Based Medical Device MD-Tissue Acts as a Mechanical Scaffold Influencing Morpho-Functional Properties of Cultured Human Tenocytes. Cells. 2020 Dec 8;9(12):2641.

EFFECTS OF COMBINED APPLICATION OF PRP AND GUNA KNEE COLLAGEN IN THE TREATMENT OF MODERATE OSTEOARTHRITIS OF THE KNEE. PILOT STUDY.

Branka Markovic MD,PhD

Faculty of sport and phusycal education, University of Belgrade, Serbia

INTRODUCTION

Multiple basic and clinical studies supporting the beneficial effects of individual PRP and collagen IA application in the treatment of OA of the knee. Potentially this two forms of treatment could have synergic effect.



METHOD

- Prospective trial , 60 patients
- Radiographically confirmed (Kellgren-Lawrence grade 2 and 3 OA)
- Previously untreated, randomly assigned to three groups (n=20 patients per group)

GROUP	TREATMENT
A	PRP
B	GUNA COLLEGEN
C	PRP + GUNA COLLAGEN

- IA application under ultrasound guidance; three time an interval of three weeks in each group
- All patients were evaluated by Knee Society Score (KSS) and Visual Analogue Scale (VAS) for pain, before the treatment and in 1, 3 and 6 months after the treatment

RESULTS

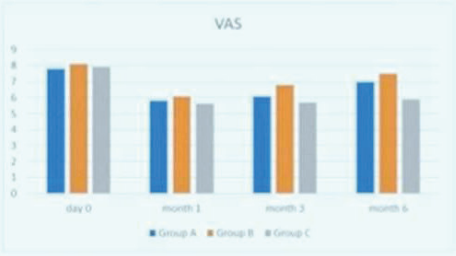

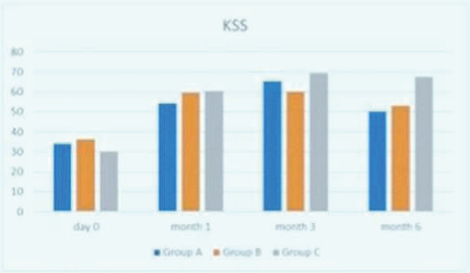

CONCLUSION

The study shows that combined PRP and GUNA collagen administration have benefitial long-term effects in the treatment of moderate knee OA symptoms.

ANKLE



HIGH-GRADE TEAR IN ACHILLES TENDINOSIS: INFILTRATION TREATMENT WITH MD TISSUE COMBINED WITH NEEDLING

A. Formis, Specialist in Physical and Rehabilitation Medicine, Head of the San Clemente Rehabilitation Unit, Mantua
A. Zanini, Orthopedic Surgeon, San Clemente, Mantua
P.F. Bettinsoli, Orthopedic Surgeon, Sant'Anna Clinical Institute, Brescia

INTRODUCTION:
The authors describe the clinical case of a nearly complete atraumatic rupture of the Achilles tendon in a patient with multiple pathologies. The patient was treated with an injection therapy using the class III collagen-based medical device GUNA MD Tissue. [1,2] The patient came to our department after a musculotendinous ultrasound scan documenting a nearly complete tear of the right Achilles tendon. He had previously been treated with antibiotic therapy (fluoroquinolone) for a bronchitis exacerbation. He reports the onset of sudden and worsening pain in the calf with functional deficit radiating to the popliteal region and progressive limping. In his medical history: post-AMI ischemic heart disease, arterial hypertension, dyslipidemia. Walking was significantly limited (2 MWT 70 m) with the aid of a cane, Thompson test ++, depression in the middle third of the Achilles tendon with the inability to walk on tiptoe. VISA scale A (3) (41/100) - NRS 8/10, BMI 22.

METHODS:
The 76-year-old patient was treated with 3 sessions of intratendinous infiltrations with collagen (MD Tissue, 2 ml) 30 days apart with associated ultrasound-guided tendon needling. The technique involves the use of a 22 Gauge needle: tendon punctures are performed, inducing microtrauma within the degenerated tendon with associated microbleeding, thus triggering an inflammatory response biologically capable of inducing a repair process.



RESULTS:
The procedure was preceded by informed consent and local anesthetic injection. An experienced surgeon performed tendon puncture according to the technique only in the first session and then intratendinous infiltration with MD Tissue. In the subsequent two sessions, only the infiltrative treatment (2 ml) was performed. No post-procedural complications occurred, and pain was controlled with analgesics. At the end of the treatment, the patient's reported pain was significantly reduced (NRS 4/10), motor autonomy improved (2MWT 125 m).

CONCLUSION:
The authors believe that the use of MD Tissue, a class III medical device based on collagen, can perfectly complement the procedure, facilitating tissue regeneration.

BIBLIOGRAPHY:

1. Randelli F. et al. "The Collagen-Based Medical Device MD Tissue ad a mechanical properties of cultured human tenocytes". Cells 2020 Dec 8;9 (12): 26
2. Randelli F. ed al. "Effect of a collagen- based compound on morpho-functional properties of cultured human tenocytes. Cells 2018 Dec 6;7 (12): 246
3. Robinson JM, Cook JL, Purdam C et al. "The VISA-A questionnaire: a valid and reliable index of the clinical severity of Achelles tendinopathy". Br J Sport Med.2001; 35 (5): 335-341
4. Chan O, et al. Percutaneous needle tenotomy for tendinopathy; A systematic review.PM;&R, 2017
5. McShane JM, et al. Sonographically guided percutaneous needle tenotomy for chronic tendinosis. J Ultrasound Med, 2006

4th ANNUAL MEETING



INJECTION TREATMENT WITH TYPE I COLLAGEN FOR ANTERIOR TALOFIBULAR LIGAMENT INJURIES IN ATHLETES: A CASE SERIES

Cristiano Fusi, Head of the Rehabilitation Department, San Martino Clinic in Malgrate, Lecco
Ennio Lopresti, Rehabilitation Department, San Martino Clinic in Malgrate, Lecco

INTRODUCTION:
The anterior talofibular ligament (ATFL) is the main ligament that laterally stabilizes the ankle joint (AJ) and is the most prone to injuries associated with twisting and inversion movements of the foot, with a higher prevalence in athletes who practice sports that require sudden changes of direction and repetitive stress on the ankle joint. Sprains of the ankle joint occur with a frequency of 1 in 10,000 subjects per day, especially among athletes. In this case series, we treated 9 patients (3 runners, 3 soccer players, 1 gymnast, 2 skaters) with infiltration therapy with type I collagen (COL1) combined with laser therapy to treat ATFL injuries and allow for faster recovery and return to sport. The therapeutic approach varies based on the severity of the sprain (grade I, II, or III) and includes conservative therapies such as: rest, ice, compression, elevation (RICE), optimal load, physiotherapy, orthotics, or surgery in the most severe cases. The use of COL1 infiltrated into the injured area acts in the proliferative phase by stimulating the synthesis of new collagen, preventing the formation of type 3 collagen that would lead to scar tissue formation, and allows functional restoration in the remodeling, repair, and tissue regeneration phase, acting as a scaffold.

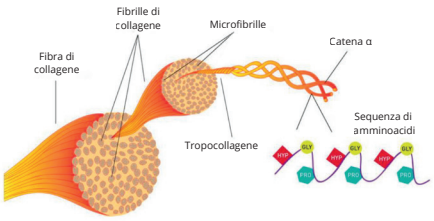

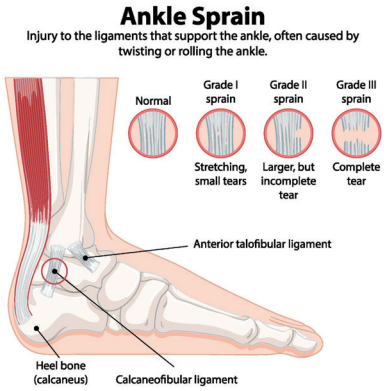

METHODS:
Nine patients (3 runners, 3 soccer players, 1 gymnast, 2 skaters) came to our attention for recent ankle sprains following a sporting event. An ultrasound scan was performed to highlight and determine the degree of injury to the ATFL. The nine patients presented mild/moderate (grade I-II) distraction injury; the joint structures that had been subjected to stress presented clinically with anterior drawer sign and slightly positive or negative talar tilting. Pain in the anterior area of the fibular malleolus was present upon palpation, with, in some cases, still swelling at the peri-malleolar level and functional limitation. The VAS scale was evaluated:
5 patients VAS at baseline 9. Final VAS 2
4 patients VAS at baseline 7. Final VAS 2
Follow-ups were performed 1 month and 3 months after the end of treatment, with evidence of decreased pain upon palpation of the ATFL, and a negative drawer test in all 9 cases. The patients were treated with 10 laser therapy sessions combined with manual drainage therapy and proprioceptive exercises during the infiltration cycle with 2 ml of COL I (MD-TISSUE, Guna S.p.A., Italy). The cycle consisted of 2 infiltrations per week for 4 weeks, peri- and intra-ligamentous under ultrasound guidance, using a 25 G, 20 mm needle.

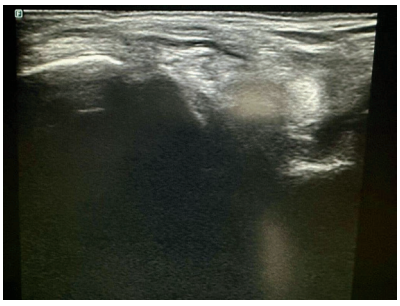

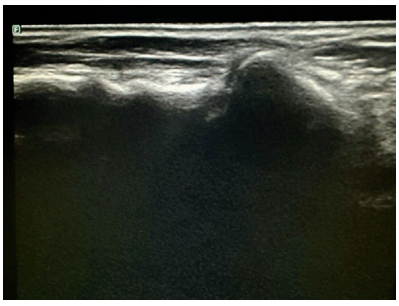

RESULTS:
At the end of the infiltration cycle, the patients reported: improvement in pain (reduced VAS), joint stability which, combined with gym training for correct load distribution, allowed a quicker return to competitive activities. The follow-up ultrasound performed 3 months after the last infiltration revealed a restoration and realignment of the ligament fibers.

CONCLUSION:
Infiltration therapy with Guna MD-TISSUE, based on porcine Type I collagen, enabled the repair and healing of the damaged ligament by reinforcing the connective tissue during the remodeling and repair phase, acting as a scaffold with a regenerative effect. As the structural component of ligaments, Type I collagen played a crucial role in tissue regeneration. This therapy allows for rapid functional recovery and a return to play for athletes with ATFL injuries.

BIBLIOGRAPHY:

1. Randelli F et al. The Collagen-Based Medical Device MD-Tissue Acts as a Mechanical Scaffold Influencing Morpho-Functional Properties of Cultured Human Tenocytes. Cells. 2020 Dec 8;9(12):2641.
2. Corrado Bruno et al. (2020). Ultrasound-guided collagen injections for treatment of plantar fasciopathy in runners: A pilot study and case series. Journal of Human Sport and Exercise. 15. S793-S805. 10.14198/jhse.2020.15.Proc3.30.
3. Baumhauer JF, Nawoczenski DA, DiGiovanni BF, Flemister AS. Ankle pain and peroneal tendon pathology. Clin Sports Med. 2004 Jan;23(1):21-34.

ISOKINETIC MEDICAL GROUP
FIFA MEDICAL CENTRE OF EXCELLENCE
Hosted by ATLÉTICO DE MADRID
XXXII ISOKINETIC CONFERENCE
FOOTBALL MEDICINE
NEW FRONTIERS
RIYADH AIR METROPOLITANO
3rd, 4th & 5th May 2025 - MADRID, Spain



INJECTABLE PORCINE COL.1 ON ATFL INJURIES: AN OBSERVATIONAL CASE-CONTROL STUDY

Dr Ennio Lopresti, *Physiatrist, Department of Rehabilitation at Clinica San Martino, Lecco and Department of Medical and Surgical Sciences, University of Catanzaro "Magna Graecia", Catanzaro Italy*
Dr Cristiano Fusi, *Physiatrist, Head of Department of Rehabilitation at Clinica San Martino, Lecco Italy*

INTRODUCTION AND PURPOSE:

The Anterior Talofibular Ligament (ATFL) the main ligament that laterally stabilizes the tibio-tarsal (TT) joint and is the most prone to injury associated with twisting and foot inverting movements. The higher prevalence is in athletes who participate in sports that require sudden changes of direction and repetitive stress on the tibio-tarsal joint.

On ankle sprains, the therapeutic approach varies depending on the severity of the sprain (Grade I, II, or III) and includes conservative therapies such as: rest, ice, compression, elevation, optimal load (PRICE), physiotherapy, orthotics, or surgery in severe cases. Type I porcine collagen is a new therapeutic opportunity, considering its properties as a scaffold and stimulation of new collagen synthesis.

This injective treatment reduces pain and improves mobility. It also prevents the formation of type III collagen, the cause of scar tissue, and allows good restoration in the remodeling, repair and tissue regeneration.

In this observational case-control study, we treated 10 patients (3 runners, 4 soccer players, 1 gymnast, 2 skaters): 6 of them were treated with type I porcine collagen (COL1) injective therapy combined with laser therapy and individual rehabilitation treatment, while 4 others (control group) were treated with individual rehabilitation treatment only.

The aim of this study was to evaluate the use of injective therapy combined with physiotherapy by highlighting any differences with physio treatment alone in sport patients with ankle sprain outcomes.

COLLAGEN FORMATION

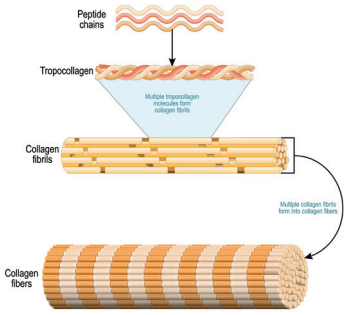

METHODS:

Ten patients (3 runners, 4 soccer players, 1 gymnast, 2 skaters) who came to our attention for recent distorsional ankle trauma following sporting event were enrolled. Ultrasound was performed to highlight and note the type of PAA injury.

The 10 patients had mild/moderate (I-II grade) distractive injury, the joint structures that suffered stresses presented clinically with anterior drawer sign and mildly positive or negative talus tilting. Pain at the level of the anterior peroneal malleolus area was present on palpation with peri-malleolar swelling and functional limitation in some case.

The VAS scale, to assess pain on palpation over the PAA, was used at 3 different times: T0 in the immediate post injury, T1 at 1 month after injury, T2 at 3 months after injury. At T0 the VAS was 7 on average for all patients examined; at T1 (in patients undergoing injective treatment) the VAS was 2 on average, in the control group the VAS was 4 on average; at T2 the VAS was for both groups 1 on average.

Patients undergoing injective treatment were also treated with 10 sessions of laser therapy combined with manual drainage therapy and proprioceptive exercises during the injective cycle with COL I porcine Guna MD-TISSUE 2 ml; while the control group only with postural proprioceptive and manual exercises. The injectable cycle in the first group included 2 injections per week for 4 weeks, peri- and intra-ligamentally under ultrasound guidance, using Needle 25 G, 20 mm.

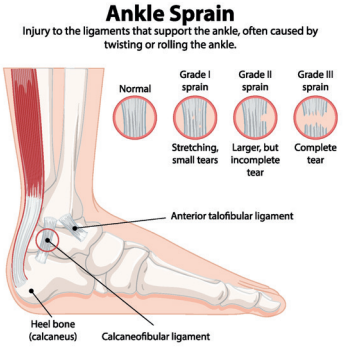

RESULTS:

Patients in the first group showed reduced VAS at T1 time (1 month) along with a greater sensation of ankle stability compared with the control group. This allowed, to associate gym training for proper load distribution and faster return to competitive activities. In the group of patients undergoing injective treatment also, the follow-up ultrasound performed at 3 months after the last infiltration revealed a restoration and proper realignment of the ligament fibers.

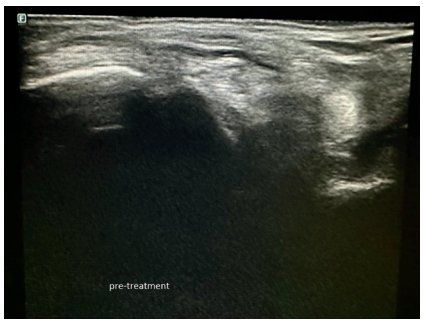

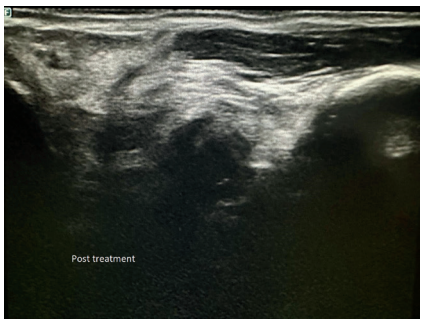

CONCLUSIONS:

Injective therapy with Guna MD-TISSUE, based on COL I porcine, enabled the repair and healing of the damaged ligament by strengthening the connective tissue in the remodeling phase by acting as a scaffold with regenerative effect.

Type I collagen, being the structural component of ligaments, played a crucial role in tissue regeneration. This doping-free therapy enables rapid functional recovery and return to play in sport patients with grade I and II LPAA injuries.

REFERENCES:

1. Randelli F et al. The Collagen-Based Medical Device MD-Tissue Acts as a Mechanical Scaffold Influencing Morpho-Functional Properties of Cultured Human Tenocytes. Cells. 2020 Dec 8;9(12):2641.
2. Corrado B. et al Ultrasound-guided collagen injections in the treatment of supraspinatus tendinopathy: a case series pilot study. J Biol Regul Homeost Agents. 2020 May-Jun;34(3 Suppl. 2):33-39.
3. Baumhauer JF. et al. Ankle pain and peroneal tendon pathology. Clin Sports Med. 2004 Jan;23(1):21-34.

SIOT 2025 ROMA
www.congressosiot.it
108° CONGRESSO NAZIONALE DELLA SOCIETÀ ITALIANA DI ORTOPEDIA E TRAUMATOLOGIA
ROMA 6-8 NOVEMBRE Centro Congressi Rome Cavalieri Waldorf Astoria

PERCUTANEOUS TENORRHAPHY OF THE ACHILLES TENDON ASSOCIATED WITH INTRATENDINOUS COLLAGEN INFILTRATION: CLINICAL EVALUATION.

Paolo Michele Boselli Manager, U.O.C. Orthopedics and Traumatology, Asst-Brianza P.O. Vimercate
Michele Cocuzza Director, U.O.C. Orthopedics and Traumatology, Asst-Brianza P.O. Vimercate

INTRODUCTION:
Subcutaneous Achilles tendon injury is a dramatic event due to its unpredictability and the resulting illness and disability. Atraumatic Achilles tendon injury is closely linked to a pre-existing degenerative tendon disease. To restore proper gait, surgical treatment (minimally invasive surgery reduces the incidence of re-ruptures and local complications) and subsequent rehabilitation are crucial. Within the first 6 months after surgery, the onset of complications and pain management were assessed using the VAS scale.

MATERIALS AND METHODS:
From January 2024 to February 2025, we treated 15 cases of acute Achilles tendon injuries, of which 14 were male and 1 female. The surgical repair technique used was the minimally invasive technique described by Ma and Griffith. Two non-absorbable sutures and one absorbable suture were used to suture the tendon. After tying the sutures visually and verifying the tendon repair, an intratendinous and peritendinous infiltration of 8 ml of collagen (MD-Tissue, Guna S.p.A., Italy) was performed. The average operating time was 30 minutes. All patients followed the same postoperative protocol: a cast in equinus and a free knee for 3 weeks. The first dressing was applied at 7 days, and the skin sutures were removed at 14 days. After removal of the valve at 3 weeks, a fixed Walker-type brace with three wedges was placed simultaneously, with the recommendation to remove one wedge per week; and progressive, protected, full weight-bearing bilaterally for a maximum of 4 weeks. After 4 weeks, free and full weight-bearing was performed without orthopedic devices and the rehabilitation program began. Nonsteroidal anti-inflammatory drugs were administered for the first 5 days after discharge and paracetamol as needed for pain. Prophylaxis with low molecular weight heparin was administered for the entire duration of immobilization. Within the first 6 months after surgery, the onset of complications and pain management were assessed using the VAS scale.





RESULTS:
No cases of re-ruptures or sural nerve entrapment were recorded. Complications included a surgical wound dehiscence (healed 5 weeks after surgery) and a case of superficial wound infection associated with intolerance of the tendon sutures (requiring a second surgical procedure for their removal 4 months after surgery). Pain management in the early post-surgical period was optimal, with VAS scores ranging from 0-3. Furthermore, no side effects were observed with the use of infiltrative collagen.

DISCUSSION:
Over the years, there has been a continuous evolution toward increasingly less invasive methods for treating Achilles tendon injuries. Indeed, invasiveness has negatively impacted surgical outcomes, leading to complications that are sometimes difficult to resolve, such as delayed healing and surgical wound dehiscence.
Minimally invasive suture techniques for acute Achilles tendon injuries can now be considered the treatment of choice. Observed advantages include: suturing the tendon within the paratenon, which reduces adhesion formation and impingement issues; the ability to directly visualize the integrity of the suture; minimal surgical scarring and tendon exposure; ease and speed of execution; and low costs.
Type I collagen is a structural glycoprotein biopolymer found notably in human tendons; an imbalance between its degradation and synthesis processes leads to tendon weakening. Literature indicates that collagen infiltration influences collagen turnover pathways: it enhances focal adhesion formation and promotes cell migration, acting as a bio-scaffold with reparative and regenerative properties.

CONCLUSIONS:
Based on our experience, we can state that the minimally invasive Achilles tendon suture technique is rapid, simple, and reliable.
Current scientific evidence suggests that injectable collagen is a safe approach with promising results for pain management; however, further prospective clinical studies are needed to more precisely define the indications and limitations of this method.
The minimally invasive suture technique combined with intratendinous collagen infiltration could play a significant role in modern Achilles tendon surgery in the near future.

BIBLIOGRAPHY:
1. Tecniche chirurgiche: focus on. Sutura mini-invasiva del tendine di Achille. Descrizione di tre tecniche chirurgiche. Magna B. et al G.I.O.T. 2010; 36: 125-130
2. Tecnica mininvasiva di riparazione del tendine di Achille- Partenza M. et al. G.I.O.T. 2006; 32: 15-20
3. Trattamento mini open della lesione sottocutanea del tendine d'Achille (nuovo strumentario). Pecchia P. G.I.O.T. 2010; 36: 50-54
4. Effect of a collagen-based compound on morpho-functional properties of cultured human tenocytes. Randelli F. et al. Cells. 2018 Dec 6; 7(12):246
5. The collagen-based medical device MD-tissue acts as a mechanical scaffold influencing morpho-functional properties of cultured human tenocytes. Randelli F. et al. Cells. 2020 Dec 8;9(12):2641

SIOT 2024 ROMA
www.congressosiot.it
107° CONGRESSO NAZIONALE DELLA SOCIETÀ ITALIANA DI ORTOPEDIA E TRAUMATOLOGIA
Roma 29-31 Ottobre Centro Congressi Rome Cavalieri Waldorf Astoria

MINIMALLY INVASIVE ACHILLES TENDON SUTURE:
COMBINED WITH INTRAOPERATIVE INJECTABLE COLLAGEN TREATMENT

PAOLO MICHELE BOSELLI[1], MICHELE COCUZZA[2]
[1] Director U.O.C. Orthopaedics and Traumatology Asst-Brianza P.O. Vimercate Director U.O.C.
[2] Orthopaedics and Traumatology Asst-Brianza P.O. Vimercate

INTRODUCTION:
Minimally invasive surgical treatment of acute complete Achilles tendon ruptures combines the benefits of surgical repair, reducing the incidence of re-ruptures, with a lower incidence of local complications compared to traditional open surgical approaches. Injective collagen therapy plays a therapeutic role in tendon injuries by exerting anti-inflammatory and pro-regenerative effects.

MATERIALS AND METHODS:
Between January and February 2024, a minimally invasive mini-open surgical technique was used to treat 4 acute Achilles tendon ruptures, involving a 3 cm longitudinal incision at the site of the lesion. The tendon repair was performed using two non-absorbable sutures according to the percutaneous approach described by the Ma and Griffith technique. After knotting the sutures and confirming the tendon repair, an intratendinous and peritendinous injection of 10 ml collagen (Guna MD-Tissue) was administered.

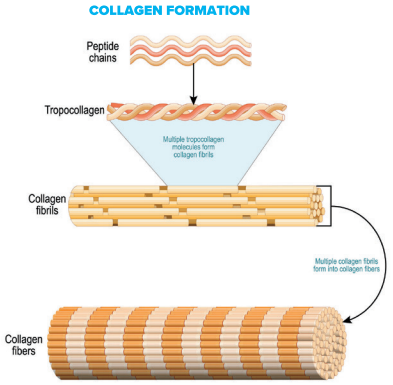

RESULTS:
Preliminary results show better postoperative pain management, promoting faster functional recovery and an earlier return to work and sports activities.

DISCUSSION:
Minimally invasive suture techniques for acute Achilles tendon injuries can now be considered the treatment of choice, based on over 30 years of experience reported in the literature since the original Ma and Griffith proposal. Collagen is a structural glycoprotein biopolymer, predominantly found in human tendons. An imbalance between collagen degradation and synthesis is responsible for the histological and functional weakening of the tendon. Key evidence supporting the use of injectable collagen comes from studies published by Randelli F. and colleagues in 2018 and 2020: this therapeutic approach influences collagen turnover pathways, improves focal adhesion formation, and promotes cell migration, acting as a bio-scaffold with reparative and regenerative properties.



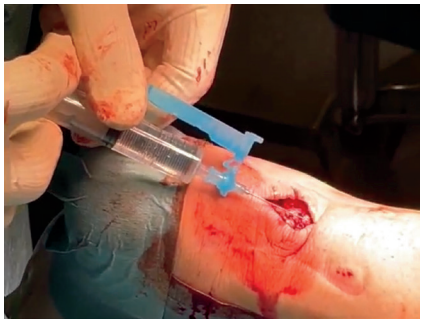

CONCLUSION:
The scientific evidence currently available suggests that injectable collagen is a safe approach with promising results in the treatment of pain and functional recovery in the musculoskeletal field. However, further clinical studies are needed to more precisely define the indications and limitations of this method.

BIBLIOGRAPHY:
1. Tecniche Chirurgiche: focus on. Sutura mini-invasiva del tendine di Achille. Descrizione di tre tecniche chirurgiche. Magna B. et al G.I.O:T. 2010;36:125-130
2. Randelli F et al. Effect of a Collagen-Based Compound on Morpho-Functional Properties of Cultured Human Tenocytes. Cells. 2018 Dec 6;7(12):246
3. Randelli F. et al. The Collagen-Based Medical Device MD-Tissue Acts as a Mechanical Scaffold Influencing Morpho-Functional Properties of Cultured Human Tenocytes. Cells. 2020 Dec 8;9(12):2641

TREATMENT OF ACHILLES TENDINOPATHY WITH INJECTABLE COLLAGEN IN DIABETIC PATIENTS: CASE SERIES

Giacomo Placella, Nicolò Biavardi; University Vita Salute San Raffaele

INTRODUCTION:

Achilles tendinopathy, a common and functionally limiting condition, has multifactorial causes that are still under debate. Among these, tendinosis is frequent and often difficult to treat with conventional therapies, frequently requiring more invasive interventions such as FAS injections or costly regenerative treatments. In this study, we propose the use of injectable collagen in patients with contraindications to corticosteroids, observing good outcomes at mid-term follow-up.

METHODS:

A cohort of 13 diabetic patients was treated with injectable collagen between March 2021 and January 2023.
All patients suffered from degenerative Achilles tendinopathy resistant to other conservative treatments and had no known allergies. The injection cycle consisted of 5 sessions of 2 ml GUNA MD-TISSUE collagen, administered at one-week intervals. Injections were performed using a 23G, 25 mm insulin needle around the tendon insertion and along its proximal course. Follow-up visits were conducted at 1 month and 6 months after the last injection, evaluating VAS scores and clinical parameters.

RESULTS:

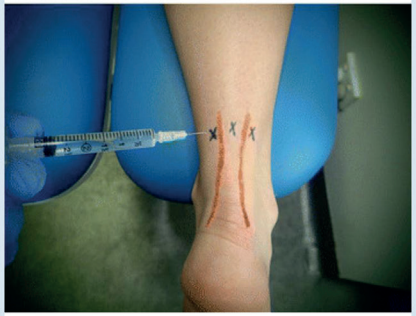

PICTURE 1: Collagen injection

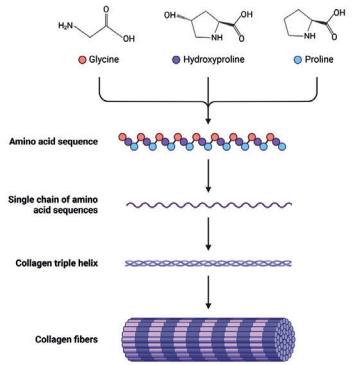

PICTURE 2: Collagen formation

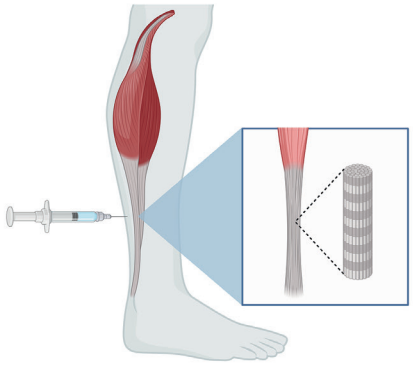

PICTURE 3: Collagen injection as an effective alternative to standard treatments

RESULTS:

All patients reported a significant decrease in VAS scores already after the second injection. No adverse reactions were observed and no local reactions occurred at the injection sites. At six months, patients were able to carry out their daily activities without the use of assistive devices or medications.

CONCLUSIONS:

The use of injectable collagen in degenerative tendinopathies may represent a valid alternative to conventional treatments, especially in patients for whom corticosteroids or other injectable drugs are contraindicated.
Given its cost-effectiveness, supporting literature, and the absence of documented adverse effects, injectable collagen can be legitimately recommended as a first-line treatment option in such cases.

BIBLIOGRAPHY:

Tecniche Chirurgiche: focus on. Sutura mini-invasiva del tendine di Achille. Descrizione di tre tecniche chirurgiche. Magna B. et al G.I.O:T. 2010;36:125-130

Randelli F et al. Effect of a Collagen-Based Compound on Morpho-Functional Properties of Cultured Human Tenocytes. Cells. 2018 Dec 6;7(12):246.

Randelli F. et al. The Collagen-Based Medical Device MD-Tissue Acts as a Mechanical Scaffold Influencing Morpho-Functional Properties of Cultured Human Tenocytes. Cells. 2020 Dec 8;9(12):2641

Created with BioRender Poster Builder

SIMFER
SOCIETÀ ITALIANA DI MEDICINA FISICA E RIABILITATIVA
The Italian Society of Physical and Rehabilitation Medicine

52° CONGRESSO NAZIONALE SIMFER
PADOVA 6 | 9 OTTOBRE 2024

CLINICA SAN MARTINO
Eccellenza Accessibile.

POSTER N. 272

COLLAGEN INJECTABLE TREATMENT FOR ANTERIOR TALOFIBULAR INJURIES IN ATHLETES: A CASE SERIES

DR. CRISTIANO FUSI
PHYSIATRIST, HEAD OF REHABILITATION DEPARTMENT AT SAN MARTINO CLINIC, MALGRATE LECCO

DR. ENNIO LOPRESTI
PHYSIATRIST REHABILITATION DEPARTMENT AT SAN MARTINO CLINIC, MALGRATE LECCO

IINTRODUCTION

Anterior talofibular ligament injuries are frequently observed in athletes participating in high-injury-risk sports such as soccer, basketball, skating, and athletics.
The anterior talofibular ligament (ATFL) is the primary stabilizer of the lateral aspect of the tibiotalar (ankle) joint and is the most frequently injured ligament during twisting and inversion movements of the foot. These injuries are particularly prevalent among athletes who engage in sports involving sudden changes of direction and repetitive stress on the foot. The anterior talofibular ligament (ATFL) is the most frequently injured structure, accounting for up to 80% of acute ankle trauma cases.
Ankle sprain is a subluxation-like event of the tibiotalar joint, during which the capsuloligamentous structures of the ankle are stressed.
Tibio-tarsal sprains occurs with a frequency of 1 in 10,000 individuals per day, especially among athletes.
This case series of 9 patients (3 runners, 3 football players, 1 gymnast, and 2 skaters) evaluates the reparative effects of injectable collagen therapy combined with laser therapy for ATFL injuries, as well as the optimal management strategies to promote re-athletisation and a faster return to play.
ATFL injuries vary in severity, ranging from mild sprains to complete ligament rupture. Common injury mechanisms include forced inversion and supination of the tibiotalar joint. ATFL injuries may result in pain, joint instability, impaired tibiotalar function, and an increased risk of recurrence.
The therapeutic approach depends on the injury severity and may include conservative treatments such as rest, ice, compression physical therapy, orthotic support, or surgical intervention in more severe cases.
Conservative treatment with injectable collagen, used as a scaffold, acts during the proliferative phase by promoting new collagen synthesis, leading to functional recovery during the remodeling and tissue repair phase.
In our case series, regenerative injection collagen-based therapy (MD-TISSUE, GUNA) was used for partial ATFL injuries in athletic patients. This approach allowed for the optimization of clinical outcomes and a faster return to sport. It is essential to adopt an individualized approach to managing talofibular ligament injuries in athletes, taking into account factors such as injury severity, level of athletic activity, and the patient's personal goals.

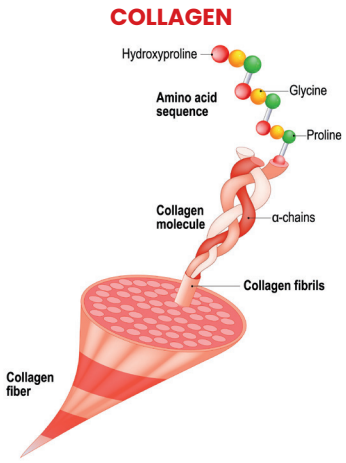

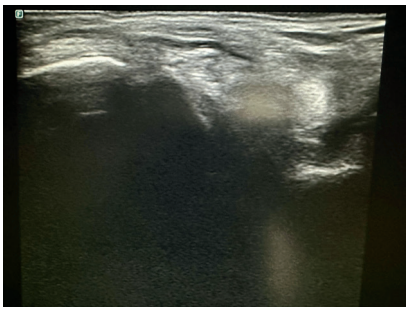

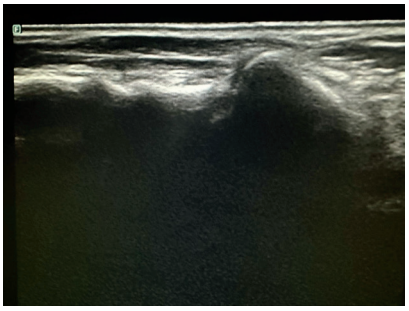

MATERIALS AND METHODS

A total of 9 patients (3 runners, 3 soccer players, 1 gymnast, and 2 skaters) presented to our clinic following recent ankle sprains sustained during sports activities. Ultrasound imaging was performed to identify and assess the severity of the ATFL injury.
The 9 cases showed mild to moderate distraction injuries. The stressed joint structures presented clinically with a mildly positive or negative anterior drawer sign and talar tilt.
Pain in the anterior region of the lateral malleolus was present upon palpation, with some cases also showing perimalleolar swelling and functional limitation.
Five patients had a VAS score of 9, while four patients had a score of 7. The final VAS score was 2. Follow-ups were conducted at 1 and 3 months after the end of treatment, showing a decrease in pain upon palpation of the ATFL, with a negative anterior drawer test in all 9 cases.
Patients were treated with 10 sessions of laser therapy combined with manual drainage therapy and proprioceptive exercises during the injection cycle with 2 ml of collagen (GUNA MD-TISSUE).
The treatment cycle consisted of 2 injections per week for 4 weeks, administered peri- and intra-ligamentously under ultrasound guidance, using a 25G, 20 mm needle.

RESULTS

At the end of the injection cycle, patients reported improvement in pain (reduced VAS scores) and joint stability, which, combined with gym training for proper load distribution, allowed for a faster return to competitive activities.
Follow-up ultrasound performed 3 months after the last injection showed restoration and reorganization of the newly formed ligament fibers.

CONCLUSIONS

Injection therapy with MD-TISSUE GUNA, a collagen bio-scaffold, promoted the repair and healing of the damaged ligament by strengthening the connective tissue during the remodeling and repair phase. It is safe, cost-effective, and helps avoid surgical interventions or more invasive therapies. Collagen, being the structural component of ligaments, played a crucial role in tissue regeneration. This innovative therapy enabled rapid functional recovery and return to play in athletic patients with ATFL injuries.

BIBLIOGRAPHY:

1. Randelli F et al. The Collagen-Based Medical Device MD-Tissue Acts as a Mechanical Scaffold Influencing Morpho-Functional Properties of Cultured Human Tenocytes. Cells. 2020 Dec 8;9(12):2641.
2. Corrado Bruno et al. (2020). Ultrasound-guided collagen injections for treatment of plantar fasciopathy in runners: A pilot study and case series. Journal of Human Sport and Exercise. 15. S793-S805. 10.14198/jhse.2020.15.Proc3.30.
3. Baumhauer JF, Nawoczenski DA, DiGiovanni BF, Flemister AS. Ankle pain and peroneal tendon pathology. Clin Sports Med. 2004 Jan;23(1):21-34.

POSTER NO. 208

SIMFER
SOCIETÀ ITALIANA DI MEDICINA FISICA E RIABILITATIVA
The Italian Society of Physical and Rehabilitation Medicine

CASE SERIES ON INJECTABLE TREATMENT WITH COLLAGEN IN PATIENTS WITH POST-TRAUMATIC ANKLE ARTHROSIS

Gabriele Mirisola[1], Giuseppe Mangone[1], Matteo Scarselli[1], Francesca Cecchi[2]

1. Rehabilitation CTO Careggi University Hospital - Florence
2. IRCCS Don Gnocchi Florence

Introduction

Arthrosis is a chronic arthropathy characterised by the destruction and potential loss of articular cartilage together with other ligamentous and joint changes, including bone hypertrophy (the formation of osteophytes). Symptoms include gradually developing pain aggravated or triggered by activity, stiffness lasting < 30 minutes on awakening after inactivity and occasional joint swelling. Osteo-ligamentous trauma or instability secondary to it or to another cause often leads to arthrotic changes. Post-traumatic ankle arthrosis accounts for the majority of causes of degenerative tibio-tarsal arthropathy.
It occurs in most intra-articular ankle injuries, often proving refractory to various types of injectable therapies, even with the correct rehabilitation and orthotic course.
The current therapeutic solutions used in the management of post-traumatic ankle arthrosis are divided into conservative and non-conservative. A conservative approach is indicated in the literature as opposed to a surgical approach.
Conservative approaches include:

- injectable corticosteroids in the acute phase of the disease
- moulded insoles and braces in the early stages of the disease
- anti-inflammatory drugs in the acute and chronic phases of the disease
- medical devices for injectable use (hyaluronic acid, mesenchymal cells, PRP, collagen) in the acute and chronic phases of the disease

The surgical approach, when pain becomes acute and the treatments described above are no longer effective, is to resort to an ankle arthrodesis or total ankle replacement. The latter offers better long-term functionality than ankle arthrodesis according to a recent study.
The aim of this study is to evaluate the efficacy of collagen injection using GUNA MD-SMALL JOINTS.
Collagen is one of the most abundant proteins in many living organisms because it plays a connective role in biological structures. It is also the most abundant protein in the extracellular matrix (ECM). The ECM is a non-cellular component within all tissues/organs and acts as a structural scaffold that can direct cell adhesion, cell migration, and regulate cell growth and metabolism.
The three polypeptide triple helix chains of GLY, PRO and HYP stabilised by interchain hydrogen bonds give the molecule high resistance to stress and tissue loading.
From the age of 40, there is an imbalance between the production and degradation of collagen, which is why it is important to stimulate its synthesis through injection.

Materials and Methods

Five patients between 40 and 72 years of age were recruited, with a total of 5 painful post-traumatic TT joints, who complained of intense pain, stiffness and a feeling of instability upon examination. All patients (with Kellgren Lorenz arthrosis grade II/III) underwent a treatment protocol involving a course of 5 ultrasound collagen injections (GUNA MD-SMALL JOINTS). Injections were performed weekly with a 23G x1" no. 16 (0.6x25mm) gauge needle. The clinical evaluation and questionnaire were performed at the initial visit preceding the first injection (T0) and one week after the last injection, i.e. 6 weeks after the first injection (T1). Follow-up is ongoing for evaluation at 3 months (T2) and 6 months (T3) from T0.

***Figure 1** : Foot x-ray*



***Figure 2:**Triple helix collagen*

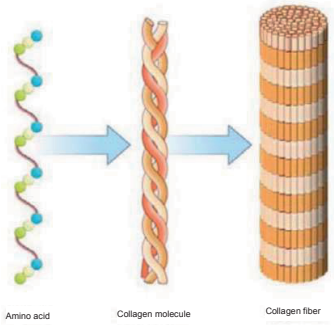

Results

Magnitudes of pain, disability, joint stability, support type (with podoscope) were assessed using the numeric pain scale (NRS) and the AOFAS questionnaire.
After the collagen injection cycle, an overall improvement of 19.8% was observed in patients with post-traumatic ankle arthrosis. The NRS scale showed an average reduction of 2.9 points, indicating a significant decrease in the patients' perceived pain. However, it is important to emphasise that these results make up a short-term assessment. Further follow-ups at 3 months (T2) and 6 months (T3) are currently underway to assess the effectiveness and duration of the benefits obtained.

Conclusions

The use of collagen injection with GUNA MD-SMALL JOINTS has proven to be an effective therapeutic approach for the treatment of post-traumatic ankle arthrosis, as it induces fibroblasts to produce more autologous collagen and increases the stability of the ankle joint.
The results showed a significant reduction in pain and related symptoms in treated patients. Due to its high biocompatibility, GUNA MD-SMALL JOINTS is an excellent therapeutic option for patients of all ages/affected by rare diseases and pregnant women. The Class III medical device does not cause any cartilage damage and does not form any micro-deposits.
These results indicate that collagen injections could be a viable alternative to conventional injectable therapies for the treatment of post-traumatic ankle arthrosis. However, further studies are needed to assess the long-term effectiveness of this approach and to confirm the benefits observed in this case series. Evaluation of the treatment from baseline data at 3 months and 6 months will make it possible to determine the duration of positive effects and provide further information on possible long-term relapses.

References

- Saltzman CL, Salamon ML, Blanchard GM, Huff T, Hayes A, Buckwalter JA, Amendola A. Epidemiology of ankle arthritis: report of a consecutive series of 639 patients from a tertiary orthopaedic center. Iowa Orthop J. 2005;25:44-6. PMID: 16089071; PMCID: PMC1888779.
- Randelli F, Menon A, Giai Via A, et al, Effect of a Collagen-Based Compound on Morpho-Functional Properties of Cultured Human Tenocytes. Cells. 2018 Dec 6;7(12):246.
- Randelli F, Sartori P, Carlomagno C, Bedoni M, Menon A, Vezzoli E, et al. The Collagen-Based Medical Device MD-Tissue Acts as a Mechanical Scaffold Influencing Morpho-Functional Properties of Cultured Human Tenocytes. Cells. 2020 Dec 8;9(12):2641.

FOOT

4th ANNUAL MEETING



INTRATENDINOUS COLLAGEN INJECTION COMBINED WITH SURGICAL TREATMENT OF ACUTE ACHILLES TENDON INJURIES

PAOLO MICHELE BOSELLI[1] , MICHELE COCUZZA[2]
[1]Manager of the Orthopedics and Traumatology Unit, Asst-Brianza Hospital, Vimercate
[2]Director of the Orthopedics and Traumatology Unit, Asst-Brianza Hospital, Vimercate

INTRODUCTION:

Minimally invasive surgical treatment of acute complete Achilles tendon injuries combines the advantages of surgery, reducing the incidence of re-ruptures, with the reduction of local complications of traditional open surgical access. Collagen injection therapy plays a therapeutic role in tendon injuries, providing anti-inflammatory and pro-regenerative effects.

MATERIALS AND METHODS:

From January to October 2024, a minimally invasive technique with mini-open surgical access was used to treat 10 acute Achilles tendon injuries, with a 3 cm longitudinal incision being made at the site of the injury. The tendon injury was sutured with two non-absorbable sutures using the percutaneous access methods described by the Ma and Griffith technique. After tying the sutures and verifying the tendon repair, a 10 ml intratendinous and peritendinous collagen injection (MD-Tissue, Guna S.p.A., Italy) was performed.

COLLAGENE

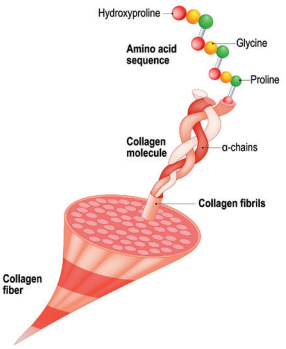







RESULTS:

Preliminary results show improved postoperative pain management, promoting faster functional recovery and an earlier return to work and sports activities.

DISCUSSION:

Minimally invasive suture techniques for acute Achilles tendon injuries can now be considered the treatment of choice, based on over 30 years of experience reported in the literature since the original proposal by Ma and Griffith. Type 1 collagen is a structural glycoprotein biopolymer, found primarily in tendons in humans. The imbalance between collagen degradation and synthesis is responsible for the histological and functional weakening of the tendon. Fundamental support for the use of infiltrative collagen was provided by the works published by Randelli F. and collaborators in 2018 and 2020: this therapeutic approach influences collagen turnover pathways, improves the formation of focal adhesions and promotes cell migration, proposing itself as a bio-scaffold with repair and regenerative action.

CONCLUSION:

The scientific evidence available to date proposes infiltrative collagen as a safe approach with promising results in the treatment of pain and functional recovery in the musculoskeletal area, however, further clinical studies are needed to more precisely define the indications and limitations of the method.

BIBLIOGRAPHY:

1. Tecniche Chirurgiche: focus on. Sutura mini-invasiva del tendine di Achille. Descrizione di tre tecniche chirurgiche. Magna B. et al G.I.O.T. 2010;36:125-130.
2. Randelli F et al. Effect of a Collagen-Based Compound on Morpho-Functional Properties of Cultured Human Tenocytes. Cells. 2018 Dec 6;7(12):246.
3. Randelli F. et al. The Collagen-Based Medical Device MD-Tissue Acts as a Mechanical Scaffold Influencing Morpho-Functional Properties of Cultured Human Tenocytes. Cells. 2020 Dec 8;9(12):2641.

3rd ANNUAL MEETING

SIAGASCOT

BARI
21-23 MARCH 2024
THE NICOLAUS HOTEL

THE TREATMENT OF ACHILLES TENDINOPATHY USING INJECTABLE COLLAGEN IN PATIENTS WITH DIABETES: CASE SERIES

GIACOMO PLACELLA
Vita-Salute San Raffaele University
San Raffaele Hospital Institute for Treatment and Research, Milan

I.R.C.C.S. Ospedale San Raffaele
San Donato Group

INTRODUCTION

Achilles tendinopathy is one of the most common syndromes caused by overuse and one of the most limiting in terms of function, in that it restricts daily activities. The causes are multifactorial and currently still controversial. Among the most common causes we have tendinosis of the tendon, which often leads to rebellious pain; it is not easily treated by traditional therapies and requires frequent injectable therapies using NSAIDS or expensive "regenerative" treatments. In patients for whom cortisone is contraindicated, we have proposed the use of injectable collagen, achieving good results at medium follow-up.

MATERIALS AND METHODS

A cohort of 13 patients with diabetes were subjected to collagen-based injectable treatments from March 2021 to January 2023. All patients were suffering from degenerative tendinopathy of the Achilles tendon resistant to other conservative treatments. None of the patients had known allergies. The injection cycle involved the injection of 2ml GUNA MD-Tissue collagen in 5 sessions at one-week intervals. The injections were performed using a 25mm 23G insulin needle around the tendon insertion and along its proximal course. The patients attended follow-up consultations 1 month and 6 months after the last injection to assess the VAS and clinical parameters.

COLLAGEN

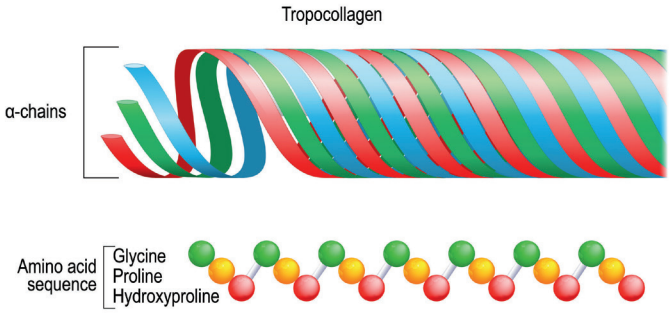

RESULTS

A significant reduction in VAS was noted in all patients even after the second injection. There were no adverse reactions or local reactions at the injection sites. After six months the patients were able to perform normal daily activities without the aid of devices or drugs.

DISCUSSION

Some studies, including a recent one (Romsaco et al.), have analysed biochemical processes resulting from collagen injection on cultures of human fibroblasts, comparing them with "untreated" fibroblasts. The fibroblasts grown with collagen developed a different morphology in the first 24 hours, with cellular rearrangements that ensured better proliferation, cellular migration and collagen production. All this occurs due to a so-called "mechanotransduction", i.e. the cell's ability to convert extracellular mechanical signals (collagen injected from the outside) into intracellular biochemical signals (gene neoexpression).

CONCLUSIONS

The use of injectable collagen in degenerative tendinopathy may be a valid alternative to traditional treatments, especially for patients for whom cortisone drugs or other injectable drugs are contraindicated Given the cost-effective benefits of the product, the supporting literature and lack of proven side effects, the use of injectable collagen can for all intents and purposes be recommended as a first line of treatment in these cases.

REFERENCES:

1. Randelli F, Sartori P, Carlomagno C, Bedoni M, Menon A, Vezzoli E, Sommariva M, Gagliano N. The Collagen-Based Medical Device MD-Tissue Acts as a Mechanical Scaffold Influencing Morpho-Functional Properties of Cultured Human Tenocytes. Cells. 2020 Dec 8;9(12):2641. doi: 10.3390/cells9122641. PMID: 33302563; PMCID: PMC7763591.
2. Corrado, Bruno & Bonini, Ilenia & Tarantino, Domiziano & Sirico, Felice. (2020). Ultrasound-guided collagen injections for treatment of plantar fasciopathy in runners: A pilot study and case series. Journal of Human Sport and Exercise. 15. S793-S805. 10.14198/jhse.2020.15.Proc3.30.
3. Godek P, Szczepanowska-Wolowiec B, Golicki D. Collagen and platelet-rich plasma in partial-thickness rotator cuff injuries. Friends or only indifferent neighbours? Randomised controlled trial. BMC Musculoskelet Disord. 2022 Dec 20;23(1):1109.

12° I.S.Mu.L.T. Congress
12-13 Aprile 2024 - Roma

CLINICA SAN MARTINO
Eccellenza Accessibile.

INJECTION TREATMENT USING COLLAGEN ON ANTERIOR PERONEAL ASTRAGALIC LIGAMENT INJURIES IN SPORTS PATIENTS: A CASE SERIES

Dr Cristiano Fusi, Physiatrist, Head of Department of Rehabilitation at Clinica San Martino, Lecco
Dr Ennio Lopresti, Physiatrist, Department of Rehabilitation at Clinica San Martino, Lecco

INTRODUCTION:

Lesions of the peroneal astragalic ligament are common among athletes in sports that involve a high risk of injury (football, basketball, skiing, athletics). The anterior peroneal astragalic ligament (LPAA) is the main ligament that laterally stabilises the tibiotarsal joint and the one most frequently subject to injury.
This case series,conducted on athletes aims to assess the reparative effects of collagen combined with laser therapy on LPAA injuries and to achieve optimal management of these lesions that enables reathletisation and quicker return to play.
We use a regenerative collagen based therapy (GUNA MD-TISSUE) for the management of partial lesions of LPAA.

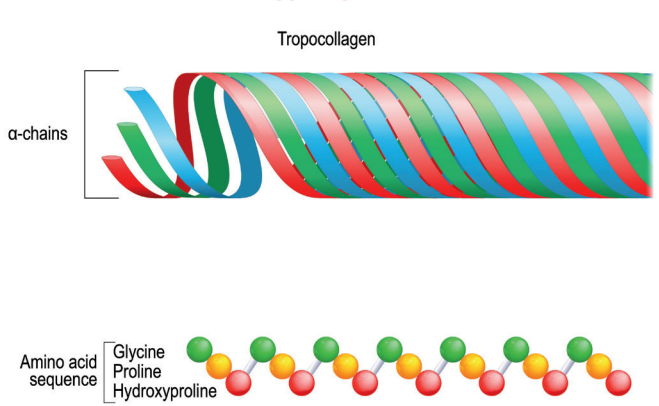

METHODS:

6 Patients (3 runners,2 football players,1 gymnast) with recent ankle sprains resulting from sporting events. An ultrasound was performed to highlight and ascertain the extent of the injury to the LPAA.
All patients presented distractive lesions but no complete lesion (mild/moderate degree); the joint structures that had been subjected to stress presented clinically with an anterior drawer sign and slightly positive or negative astragalic tilting.
Pain upon palpation was experienced in the anterior region of the peroneal malleolus with,in some cases, some remaining swelling in the perimalleolar area and functional limitation.
3 patients had a VAS score of 9, 3 score of 7.
The patients were given 10 laser therapy sessions combined with manual draining therapy and proprioceptive exercises, undertaken during injection with 2 ml Guna collagen MD-TISSUE.
Cycle: 2 injections a week for 4 weeks by the peri and intra-ligament route under ultrasound guidance, 25G, 20 mm needle.

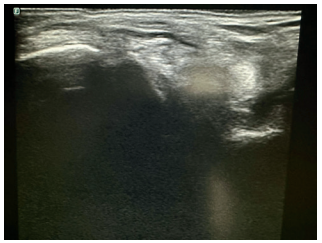

PAA tendon after injury

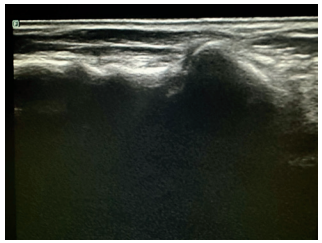

PAA tendon after collagen injections

RESULTS:

Follow-ups were carried out 1 month and 3 months after completion of the treatment, with a reported reduction in pain on palpation of the anterior peroneal astragalic ligament, and a negative drawer test in all 6 cases.
On completion of the injection cycle the patients reported: an improvement in pain (reduced VAS, final score was 2), stability of the joint which, combined with training in the gym to obtain correct load distribution, enabled a quicker, more effective return to competitive activity.
The check-up ultrasound performed 3 months after the last injection showed evidence of restoration and realignment of new ligament fibres.

Injection therapy using Guna MD-TISSUE, a bioscaffold based on collagen, enabled the repair and healing of the damaged tissue during the proliferative phase, and leads to the healing of the ligament and functional restoration during the remodelling phase.

CONCLUSIONS:

Collagen is a fundamental structural component of ligaments and therefore played a crucial role in the tissue regeneration. This therapy, which acts on the biology of anterior peroneal astragalic ligament repair, has proven safety and cost-effectiveness, and avoids the need for surgery or more invasive treatment. Collagen played a vital role in the synthesis of new collagen, realigning damaged fibres and strengthening the connective tissue during remodelling and repair. For sports patients with anterior peroneal astragalic ligament injuries, this innovative therapy has improved the clinical picture, with rapid recovery of function and return to play.

REFERENCES:

1. Randelli F et al. The Collagen-Based Medical Device MD-Tissue Acts as a Mechanical Scaffold Influencing Morpho-Functional Properties of Cultured Human Tenocytes. Cells. 2020 Dec 8;9(12):2641.
2. Corrado Bruno et al. (2020). Ultrasound-guided collagen injections for treatment of plantar fasciopathy in runners: A pilot study and case series. Journal of Human Sport and Exercise. 15. S793-S805. 10.14198/jhse.2020.15.Proc3.30.
3. Baumhauer JF, Nawoczenski DA, DiGiovanni BF, Flemister AS. Ankle pain and peroneal tendon pathology. Clin Sports Med. 2004 Jan;23(1):21-34.



The use of collagen-based medical devices in the treatment of Morton's neuroma: a case series

Federico Giarda[1], Adele Agostini[2], Stefano Colonna[1], Davide Dalla Costa[1], Rosa Rogliani[1], Luciana Sciumè[1], Salvatore Ciriolo[1], Giovanna Beretta[1]

1 Department of Rehabilitation Medicine and Neurorehabilitation, Department of Neurosciences, Local Social and Healthcare Area of Niguarda Grand Metropolitan Hospital, Piazza dell'Ospedale Maggiore 3, Milan, Italy.
2 Department of Biomedical Sciences for Health, University of Milan, Milan, Italy.

Introduction Morton's neuroma is a compressive neuropathy of the common plantar digital nerve. The conservative approach is the first recommended treatment option, frequently involving injectable therapies based on ethanol, sclerosants or cortisone. (1) These latter in particular have proven effective in reducing pain, mainly in the short term, with uncommon but non-negligible side effects. (2) Previous work has demonstrated the potential of collagen-based medical devices in facilitating homeostasis and tissue repair, behaving as an active biological scaffold on the extracellular membrane, with no significant side effects yet reported. (3) There are no previous studies that describe the injectable use of collagen in the treatment of Morton's Neuroma. The aim of this case series is to assess their efficacy in reducing pain and improving function in the short to medium term.

Materials and Methods Three female patients, aged between 51 and 62 years and suffering from symptomatic, radiologically-demonstrated Morton's neuroma, were enrolled. The patients were given three injections, at weekly intervals, of collagen (2ml) added to 2ml of 2% lidocaine hydrochloride using a 26G (13mm) needle. The injections were carried out via dorsal access, in the distal intermetatarsal spaces, with indirect ultrasound guidance (Figure 1). The results, in terms of improved function and pain control, were assessed using the AOFAS (American Orthopaedic Foot and Ankle Society) questionnaire, and according to the VNS (Visual Numeric Scale) for pain (assessed both at rest and during activity), administered before, during (T0, T1 and T2), and on completion of 6 months of treatment (T3-5; Table 1).

Figure 1: *injection of collagen.*



Treatments and follow-up of patients	
T0	Before first injection
T1	Before second injection
T2	Before third injection
T3	Check-up after 1 month of treatment
T4	Check-up after 2 months of treatment
T5	Check-up after 3 months of treatment

Table 1: *Treatments and follow-up of patients. The three applications coincided with the first three follow-ups at points T0, T1 and T2.*

Statistical analysis was performed using the PRISM Graphpad 6.0 software, with two-way ANOVA analysis using the Bonferroni comparative test, taking the T0 follow-up time as the point of comparison. Values of $p<0.05$ were considered to be significant.

70

Results During the observation period, all patients treated experienced a significant reduction in painful symptoms when at rest as early as one week after the first session, with a gradual improvement, in terms of both pain and function, reported in the subsequent follow-ups (Figure 2). There was a significant reduction in pain, even during activity, reaching values clearly lower than those initially reported (Figure 2). The average score on the AOFAS scale gradually increased from 58.67/100 to 82.67/100 (T0 vs T3; Figure 2A) showing statistical significance even between patients and maintaining the improvement in function at six months (T5: average value 85.33/100: CI: 75.00-91.00; **p=0.0002**; Figure 2A). The average resting VNS score for pain went from 8.00/10 to 2.33/10 in resting conditions (T0 vs T3; T5: average value 3/10: CI: 1.00-3.00; **p<0.0001**; Figure 2B), and from 9.00/10 to 3.33/10 during activity (T0 vs T3), with further reductions found at the final, six month check-up (T5: average value 3.00/100: CI: 2.00-5.00; **p=0.0004**; Figure 2C). Two patients experienced moderate pain (2/10) only during activity, and one patient reported pain of mild intensity at rest (3/10) and medium intensity during activity (5/10). None of the patients reported pain resulting from the treatment, and no local or systemic adverse events were reported.

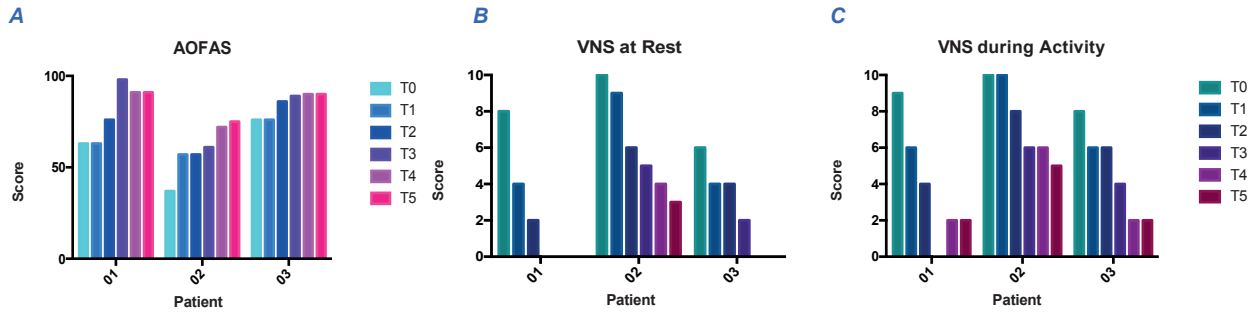

Figure 2: *Graphical representation of results; Results of AOFAS score in the three patients (Figure 2A) and results of VNS score at rest (Figure 2B) and during activity (Figure 3C). Figure 2A Two-way ANOVA test (p=0.0002); Figure 2B Two-way ANOVA test (p<0.0001); Figure 2C Two-way ANOVA test (p=0.0004).*

Conclusions

Collagen-based medical devices for injectable use are proposed as a safe, effective, easily applied option in the treatment of pain and functional limitation resulting from Morton's neuroma. However, further studies with a larger number of cases and experimental assays in the preclinical and clinical phases are required to better understand the mechanism of action and confirm its potential for use in compressive neuropathy.

References

1) Bhatia M, Thomson L. Morton's neuroma - Current concepts review. J Clin Orthop Trauma. 2020 May-Jun;11(3):406-409.
2) Brinks A, Koes BW, Volkers AC, Verhaar JA, Bierma-Zeinstra SM. Adverse effects of extra-articular corticosteroid injections: a systematic review. BMC Musculoskelet Disord. 2010 Sep 13;11:206.
3) Randelli F, Sartori P, Carlomagno C, Bedoni M, Menon A, Vezzoli E, et al. The Collagen-Based Medical Device MD-Tissue Acts as a Mechanical Scaffold Influencing Morpho-Functional Properties of Cultured Human Tenocytes. Cells. 2020 Dec 8;9(12):2641.

MUSCLES

ISOKINETIC MEDICAL GROUP
FOOTBALL MEDICINE
BRIDGING SCIENCE AND PRACTICE
FIFA MEDICAL CENTRE OF EXCELLENCE
CÍVITAS METROPOLITANO STADIUM
25th, 26th, 27th May 2024 • MADRID, Spain



EFFICIENCY AND SAFETY OF COLI INJECTIONS FOR TREATMENT OF HAMSTRING TENDINOPATHY

SARINO RICCIARDELLO MATTEO BALDASSARRI, DIEGO GHINELLI, LUCA PERAZZO, ROBERTO BUDA
Hospital VILLA LAURA BOLOGNA

INTRODUCTION AND PURPOSE:

Hamstring injuries are one of the most common types of injuries affecting athletes and sportive people. Despite this, the optimal management of hamstring muscle injuries is not well defined. The main symptom of proximal hamstring tendinopathy (PHT) is lower gluteal pain, especially during running or prolonged sitting. Traditional treatment methods for PHT are by the majority comparable to those of other tendinopathies: they include rest and ice for symptoms relief in the initial phase, reduction or pause of sports activity, nonsteroidal anti-inflammatory drugs (NSAIDs), soft tissue mobilization, physiotherapy and continuous home exercise program focusing on progressive eccentric hamstring strengthening and core stabilization. Novel therapeutic approaches are recognized including shockwave (SWT) and ultrasound (US) therapy, ultra-sound-guided corticosteroid injection and Platelet rich plasma (PRP) injection. US-guided corticosteroid injection of the tendons heath is used in PHT. However detrimental effects such as slowed long-term tissue healing caused by inhibition of collagen linkage, incomplete healing and recurrent injury have been reported. Additionally, symptoms often recur after initial good short-term results. Collagen injections (COLI) represent a novel biological approach to treat tendinopathies and musculotendinous reconstructions; they are also considered a cost effective, easy to use and regenerative solution. Purpose of the study is to determine the efficacy of an ultrasound-guided GUNA collagen injection in the treatment of patients with PHT.

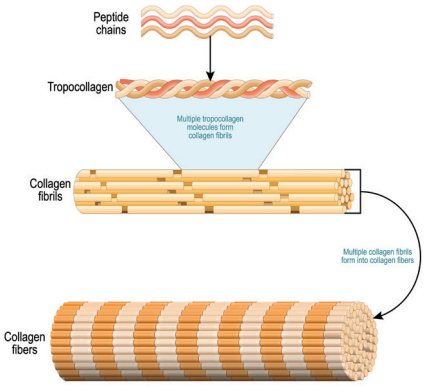

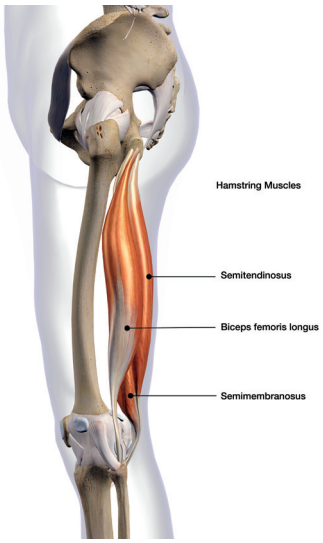

METHODS:

Twenty-eight patients diagnosed with an acute hamstring injury were randomly allocated to ultrasound-guided GUNA collagen injection with needle of 21G (COLL group) combined with a rehabilitation program, or to a rehabilitation program only. The primary outcome of this study was time to return to play. In addition, changes in pain severity and pain interference scores over time were examined. Administration of n. 2 injections of 4ml of MD-MUSCLE (performed weekly under ultrasound guidance confirmed on magnetic resonance imaging (MRI). Pain, function and sporting activity were tested with the Victorian Institute of Sport Assessment-Proximal Hamstring Tendons (VISA-H) questionnaire, administered before injections and at 8-weeks follow-up.

RESULTS:

The study sample consisted of 20 males and 8 females with a mean age of 30.2 years. Patients in the COLL group achieved full recovery significantly earlier than controls (P = .02). The mean time to return to sport was 56.7 ± 7.0 days and 72.5 ± 20.6 days for the COLL and Rehabilitation group, respectively (t (22) = 2.50, P = .02).
Both groups started with similar VISA-H scores (mean: 43.90); after with 6- week post-injection COLL group VISA-H scores (mean: 62.14) otherwise Rehabilitation group had lower results (mean : 57.34), no statistically significant difference was found (p = 0.14). When performing separate analyses for patients with mild (n = 9), moderate (n = 16) or marked (n = 4) PHT, no statistically significant difference was found in pre-and post-injection VISA-H scores for any of the groups (p = 0.86, p = 0.13, p = 0.28 respectively), although patients with moderate or marked degree improved faster.

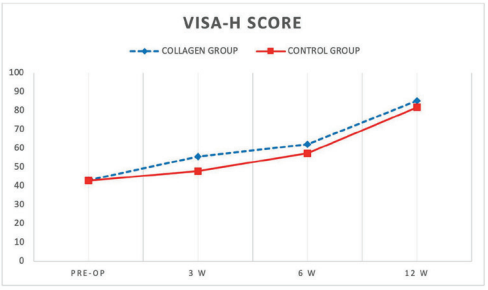

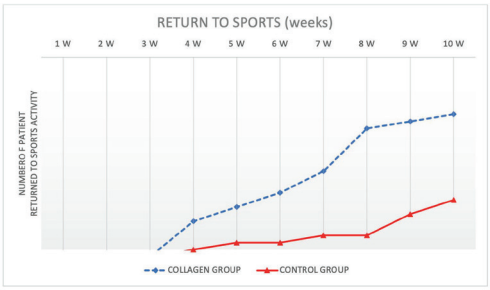

CONCLUSIONS:

The protocol used in patients with PHT, carrying out the injections of MD-Muscle collagen combined with a dedicated rehabilitation program, was significantly more effective in the treatment of femoral biceps lesions than the rehabilitation program alone. The injection treatment with Guna collagen medical device represents a valid reparative therapy, useful, safe, easy to use and cost-effective. Collagen can be associated with physical therapies, accelerating the regenerative process. In addition, the use of the ultrasound guidance facilitates the targeted deposition of collagen, compared to the freehand approach. MD-Muscle significantly reduced pain by exerting an antioxidant and anti-inflammatory activity. It promotes homeostasis, remodeling and repair of tissues, by acting as an active scaffold at the level of the extracellular membrane.
Guna collagen allows to act on the reparative and regenerative phase, with a biological response that made it possible to speed up return to the sportive activity.

REFERENCES:

1. Randelli F, Sartori P, Carlomagno C, Bedoni M, Menon A, Vezzoli E, Sommariva M, Gagliano N. The Collagen-Based Medical Device MD-Tissue Acts as a Mechanical Scaffold Influencing Morpho-Functional Properties of Cultured Human Tenocytes. Cells. 2020;9(12):2641.
2. Lempainen L, Johansson K, Banke IJ, Ranne J, Mäkelä K, Sarimo J, Niemi P, Orava S. Expert opinion: diagnosis and treatment of proximal hamstring tendinopathy, MLT J. 2015;5(1):23-8.
3. Godek P, Szczepanowska Wolowiec B, Golicki D Collagen and platelet-rich plasma in partial-thickness rotator cuff injuries. Friends or only indifferent neighbours? Randomised controlled trial. BMJ. 2022;23(1):1109.

NOTES



PLAY SURE
doping free

GUNA
medical device

GUNA S.p.a.
Via Palmanova, 71 - 20132 Milan - Italy
T. +39 02 280181 - export@guna.it
collagenmd.guna.com

GUNA S.p.a. is a company with quality management standard system **ISO 9001** certified by Bureau Veritas Italia SpA

7EX145 B